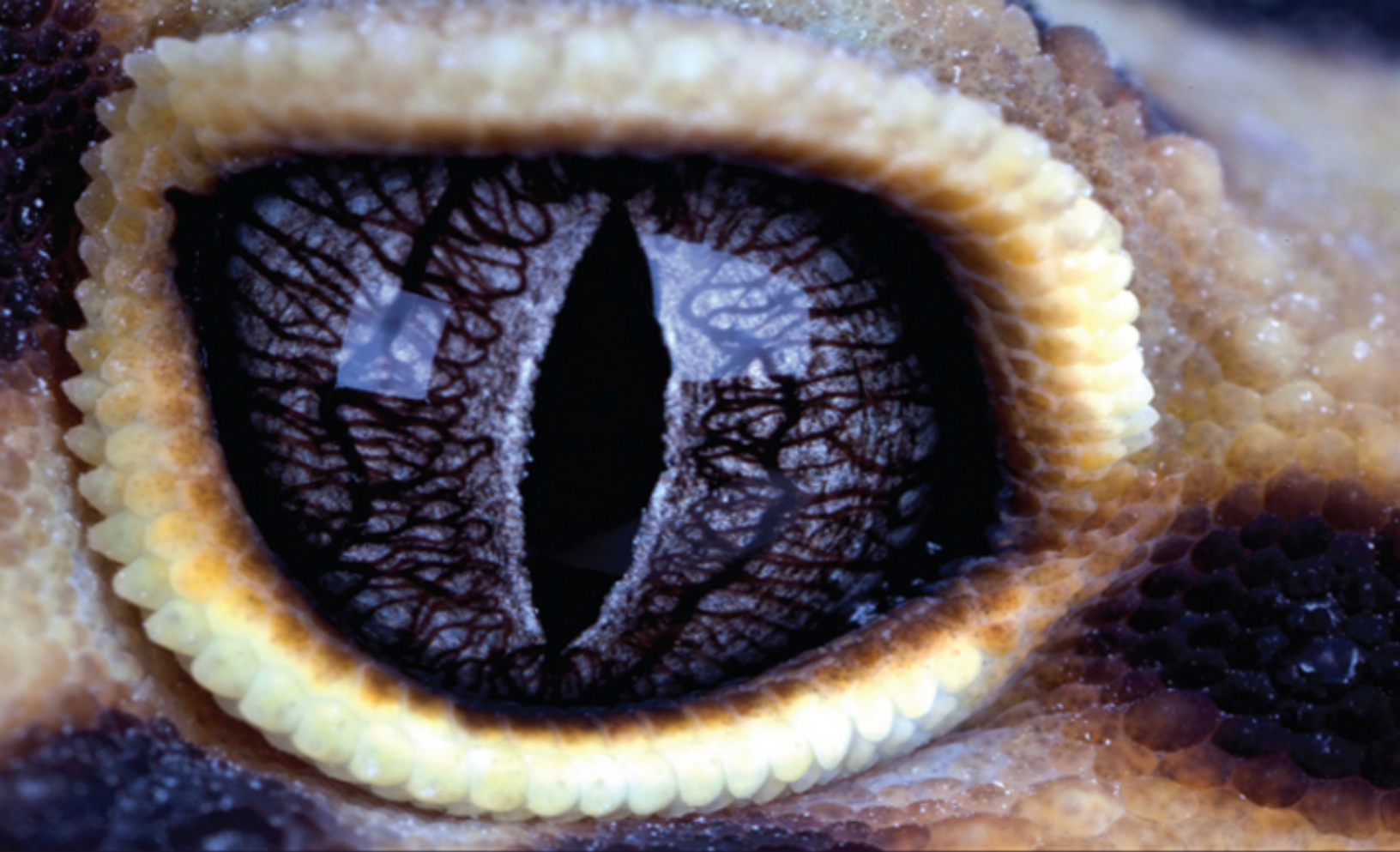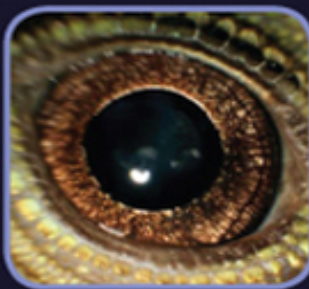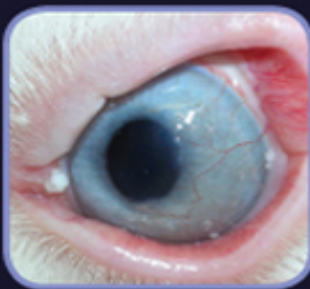




Ophthalmology of Exotic Pets



DAVID L. WILLIAMS

 WILEY-BLACKWELL

Table of Contents

Cover

Title page

Copyright page

Foreword

Acknowledgements

Dedication

Chapter 1 Introduction

Chapter 2 A brief history of comparative ophthalmology

Chapter 3 Common features of exotic animal ophthalmology

Ocular examination

Ancillary tests

Ocular pharmacology

Chapter 4 The rabbit eye

Introduction

Anatomy and physiology of the rabbit eye

What do rabbits see?

[Adnexal disease](#)
[Diseases of the orbit](#)
[Diseases of the cornea](#)
[Diseases of the lens](#)
[Diseases of the iris](#)
[Glaucoma](#)
[Retinal disease](#)

[Chapter 5 The guinea pig eye](#)

[Anatomy and physiology of the guinea pig eye](#)
[What do guinea pigs see?](#)
[Diseases of the guinea pig eye](#)

[Chapter 6 The ferret eye](#)

[Anatomy and physiology of the ferret eye](#)
[What do ferrets see?](#)
[Diseases of the ferret eye](#)

[Chapter 7 The rat and mouse eye](#)

[Anatomy of the eye](#)
[A note on ophthalmoscopy](#)
[What do rats and mice see?](#)
[Ophthalmic disease in rats and mice](#)

[Chapter 8 The eye of other mammalian exotic pet species](#)

[Introduction](#)
[Hamsters](#)

[Gerbils](#)
[Chinchillas](#)
[Degus](#)
[Hedgehogs](#)
[Primates](#)

[Chapter 9 The avian eye](#)

[Introduction](#)
[Anatomy and physiology of the avian eye](#)
[What do birds see?](#)
[Evaluating the avian eye](#)
[Orbital disease](#)
[Lid and adnexal disease](#)
[Corneal disease](#)
[Uveal disease](#)
[Lens disease](#)
[Retinal disease](#)
[Horner's syndrome](#)
[Enucleation](#)

[Chapter 10 The reptile eye](#)

[Introduction](#)
[Anatomy and physiology of the reptilian eye](#)
[Biology of the reptilian spectacle](#)
[What do reptiles see?](#)
[Diseases of the reptile eye](#)

[Chapter 11 The amphibian eye](#)

Anatomy and physiology of the amphibian eye

What do amphibians see?

Diseases of the amphibian eye

Enucleation

Conclusion

Chapter 12 The fish eye

Introduction

Anatomy and physiology of the fish eye

What do fish see?

Diseases of the aquarium fish eye

Conclusions

Index

Ophthalmology of Exotic Pets

David L. Williams

MA VetMB PhD CertVOphthal CertWEL FHEA FSB FRCVS

*Associate Lecturer in Veterinary Ophthalmology
Department of Clinical Veterinary Medicine
University of Cambridge, UK*

 **WILEY-BLACKWELL**

A John Wiley & Sons, Ltd., Publication

This edition first published 2012 © 2012 by David Williams
Wiley-Blackwell is an imprint of John Wiley & Sons, formed
by the merger of Wiley's global Scientific, Technical and
Medical business with Blackwell Publishing.

Registered office: John Wiley & Sons, Ltd, The Atrium,
Southern Gate, Chichester, West Sussex, PO19 8SQ, UK

Editorial offices: 9600 Garsington Road, Oxford, OX4 2DQ,
UK

The Atrium, Southern Gate, Chichester, West Sussex, PO19
8SQ, UK

2121 State Avenue, Ames, Iowa 50014-8300, USA

For details of our global editorial offices, for customer
services and for information about how to apply for
permission to reuse the copyright material in this book
please see our website at www.wiley.com/wiley-blackwell.

The right of the author to be identified as the author of this
work has been asserted in accordance with the UK
Copyright, Designs and Patents Act 1988.

All rights reserved. No part of this publication may be
reproduced, stored in a retrieval system, or transmitted, in
any form or by any means, electronic, mechanical,
photocopying, recording or otherwise, except as permitted
by the UK Copyright, Designs and Patents Act 1988, without
the prior permission of the publisher.

Designations used by companies to distinguish their
products are often claimed as trademarks. All brand names
and product names used in this book are trade names,
service marks, trademarks or registered trademarks of their
respective owners. The publisher is not associated with any
product or vendor mentioned in this book. This publication is
designed to provide accurate and authoritative information
in regard to the subject matter covered. It is sold on the

understanding that the publisher is not engaged in rendering professional services. If professional advice or other expert assistance is required, the services of a competent professional should be sought.

Library of Congress Cataloging-in-Publication Data

Williams, David L., MA.

Ophthalmology of exotic pets / David L. Williams.

p. ; cm.

Includes bibliographical references and index.

ISBN 978-1-4443-3041-0 (pbk. : alk. paper)

ISBN 978-1-4443-6124-7 (epdf)

ISBN 978-1-4443-6125-4 (epub)

ISBN 978-1-4443-6126-1 (mobi)

I. Title.

[DNLM: 1. Eye Diseases--veterinary--Handbooks. 2. Pets--Handbooks. SF 891]

LC classification not assigned

636.089'77--dc23

2011034163

A catalogue record for this book is available from the British Library.

Wiley also publishes its books in a variety of electronic formats. Some content that appears in print may not be available in electronic books.

Foreword

The light of the body is the eye: therefore when thine eye is single, thy whole body also is full of light: but when thine eye is evill, thy body also is full of darknesse.

Gospel of St Luke 11: 34. King James Version (1611)

The importance of the eye, in terms of health, is emphasised in the quotation above. St Luke is believed to have been a physician. The eye in its different forms has long attracted interest and attention.

In geological time light-sensitive structures appeared long before the vertebrate eye. Photoreceptors in single-celled organisms permitted the latter to be aware of light and, if necessary, to respond to it by moving or changing behaviour (photoperiodism) but the cells were not sufficiently complex to facilitate detailed navigation nor, indeed, to interpret light in any detail. Simple photoreception has, however, enabled many extinct and extant single-celled organisms to take maximum advantage of sunlight for photosynthesis and move towards it. Insofar as complex eyes are concerned, fossils representing the early appearance of such date back 500-550 million years ago, to the period of rapid evolutionary change that is commonly called the 'Cambrian Explosion'. This resulted in the appearance of a wide range of ocular structures, which differed in acuity, the range of wavelengths that they could detect and whether they could differentiate colours.

The origin and evolution of the eye has attracted much scientific investigation and, interestingly, both academic and public debate. The detail and apparent sophistication of the mammalian eye even prompted Charles Darwin at one stage to query whether such a structure could really have evolved as a result of tiny changes over a period of time.

This same question and the argument it provokes continue to fascinate many of different persuasions who, rather than studying and analysing the diverse information and opinion that is available, prefer to use the issue to promulgate their views about the origin and significance of life. Whatever the rights and wrongs of the different arguments, none of the discussants expresses any doubt about the exquisite beauty of the eye and its importance in biology and survival!

In this book, David Williams, a veterinary surgeon with a deep interest in comparative medicine and many years' experience as an ophthalmologist, provides information and guidance about the ocular disorders of 'exotic pets'. He interprets the latter term as meaning those species that are commonly kept as companion animals but which fall outside the traditional teaching remit of the veterinary curriculum (in his words, 'non-dog-and-cat species'). His approach in the text is refreshingly personal, the prose often taking the form of familiar conversational English or expressed as a rhetorical question. This helps make this a very readable book as well as a volume that is steeped in extensive personal experience, sound clinico-pathological description and strongly evidence-based advice.

I have known Dr David Williams for many years and have always been impressed by his energy, industry and enthusiasm. These attributes have spanned the period since he worked with me as a student - and brought a new dynamism to my laboratory - to the present day, when he has evolved into a respected academic and a much appreciated teacher and mentor. His deep interest in the history of his subject, as illustrated in the introductory chapter of this book as well as his choice of images, prompts me to liken him to one of my own heroes. Jan Swammerdam (1637-1680) was a member of the Dutch school of anatomy, and, amongst many other scientific and religious pursuits, despite a traumatic period in his life,

dissected and described the morphology of a whole range of vertebrate and (especially) invertebrate animals. In particular, Swammerdam performed the first comprehensive scientific studies on the anatomy of the honey bee, *Apis mellifera*, which included research on the compound and simple eyes of the species. He showed that painting over the eyes of honey bees caused them loss of sight and, using very basic microscopical equipment, he sketched the minute ocular structures that he saw, such as pigment granules and the corneal facets, those elongated crystalline cones that are typical of the species. David Williams is very much in the same mould; he shares Swammerdam's fascination with the mysteries of the natural world and he is endowed with comparable dedication to his subject and attention to detail.

'Nanos gigantium humeris insidentes'; those of us with a passion for the study of comparative medicine and its application to diverse species are mere dwarfs compared with the pioneers who, decades ago, investigated and marvelled at what were described by Darwin as 'endless forms most beautiful and most wonderful'. David Williams is conscious of these antecedents and in his book he pays generous tribute to those, both from the present and the past, who have helped pave the way for his many achievements.

The provision of proper veterinary attention to exotic pets is essential if these animals, which play an important part in society by providing companionship and education, are to thrive. Specialist texts are greatly needed and this volume by David Williams will admirably fill the gap as far as the ophthalmology of exotic pets is concerned. It will, I believe, not only provide advice of the highest quality but also prove fun to read and to use. I wish it well.

John E Cooper, DTVM FRCPath FSB CBiol FRCVS
RCVS Specialist in Veterinary Pathology

Diplomate, European College of Veterinary Pathologists
European Veterinary Specialist, Zoological Medicine
Faculty of Veterinary Medicine, University of Nairobi, Kenya
Department of Veterinary Medicine, University of
Cambridge, UK
Durrell Institute of Conservation and Ecology (DICE),
The University of Kent, UK.

Acknowledgements

To all who provided my education in exotic ophthalmology, cases to see and images to borrow: most particularly John Cooper, Elliott Jacobson, Steve Barten, Kathy Barrie, Willy Wildgoose, Peter Lee, Sheila Crispin and Graham Martin.

Dedication

*To Jennie, who puts up with me spending far too much time
in the chaos of my study, and to Sam, Jack and Ross, who
live with my gruesome eye images on screen and exotic
eyeballs in pots, here there and everywhere!
And not forgetting God, who designed all these wonderful
eyes in the first place!*

Chapter 1

Introduction

The quite remarkable feature of eyes across vertebrate species from the axolotl to the zebra is their similarity. The basic design of the eye, the cornea, the iris, the lens, the retina all enclosed in a tough collagenous sclera, is duplicated throughout vertebrate species, as are the similar functions across the animal kingdom with light refracted to form an image on the retina where the photoreceptors transform the incident photon's energy into an electrical signal.

And yet these eyes have many differences in both their anatomy and their pathology: their appearance when normal and abnormal. Let's face it, if this were not the case there would honestly be no need for this book! From the differences in conjunctival responses to infectious organisms to the variation in vascular anatomy of the orbit in the rabbit as compared to that of the dog and cat we are more used to enucleating, it is vital to understand the variation in anatomy and physiology, in pharmacology and pathology between the eyes of fish, amphibians, reptiles, birds and mammals.

Indeed this could be replicated across body systems but not perhaps quite so dramatically as in the eye. There is a dichotomy in exotic animal veterinary medicine. On the one hand quite a substantial proportion of what we understand about the diseases of cats and dogs, their aetiopathology and their management can be extrapolated to help us deal with disease in less familiar species, be they raptors or rabbits. But on the other hand there are differences

between hounds, hamsters and horned toads that make extrapolation without due care and attention potentially ineffective or even dangerous.

Hopefully this volume will aid in identifying where extrapolation from canine and feline ophthalmology can be made and where new information is necessary. We start with areas where extrapolation is possible, the first of these being the straightforward techniques of ocular examination, which may, in many cases, be transferred from conventional companion animal species. Even here though, differences exist.

Before we continue, however, it may be that this is an appropriate point to make two confessions. First some might complain that there are several areas of duplication in the text. The book is designed with the assumption that many will not read it through from cover to cover, but rather use it as a reference dipping in to specific ocular diseases in particular species. Thus several areas are necessarily somewhat duplicated to ensure that the information needed is presented in a readily accessible form. Second it might be necessary to give an apology to some for the wording of the title of this book 'Ophthalmology of Exotic Pets'. For some, it must be noted, rabbits and guinea pigs are hardly exotic species; recent evidence suggests that rabbits are the third most common species seen in small animal veterinary practice, certainly here in the United Kingdom and quite possibly elsewhere also. Nevertheless in many ways, from their teeth to their retinas, rabbits and guinea pigs are very different from cats and dogs and so they deserve inclusion in a volume detailing ophthalmic disease in what we might term non-dog-and-cat species. But that would hardly make an appropriate title for a book like this would it?! My first reason for producing a volume on this subject came when seeing how useful Sue Paterson's volume 'Skin Diseases of Exotic Pets' was [1]. Sue cleverly gathered a group of other

dermatologists with special interests in different exotic species to write her book with her, but somehow I failed to galvanise others in the field of veterinary ophthalmology to produce a similar volume. I hope that those with greater expertise and experience in the fields of reptile, avian and laboratory animal ophthalmology will forgive any resulting failings in this book. Perhaps a second edition can include their contributions to the subject.

Reference

1. Paterson S. *Skin Diseases of Exotic Pets*. Oxford: Blackwell Publishing, 2006.

Chapter 2

A brief history of comparative ophthalmology

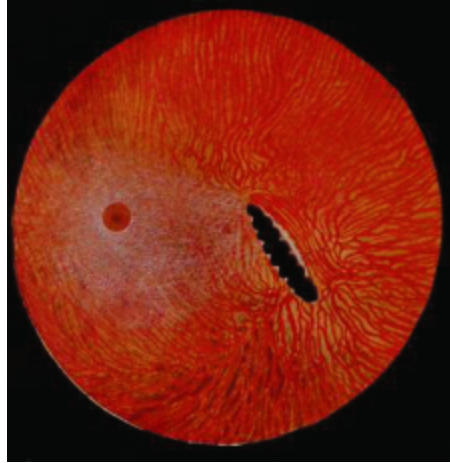
While we may think that a text on exotic animal ophthalmology is a new venture, and certainly within veterinary ophthalmology this is the first volume dedicated to the subject, ophthalmologists and visual scientists have for many years considered the delights of comparative ophthalmology worth pursuing. The great Sir Stewart Duke Elder started his momentous 16 volume *System of Ophthalmology* with a glorious first volume entitled 'The Eye in Evolution', covering ocular anatomy and physiology together with visual ecology and behaviour from invertebrates through to higher mammals. But 50 years earlier the Canadian ophthalmologist Casey Albert Wood (Figure [2.1](#)) was already publishing his remarkable overview of avian ophthalmology *The Fundus Oculi of Birds as Viewed with the Ophthalmoscope* linking his lifelong interest in ornithology with his acknowledged expertise in ophthalmology.

Figure 2.1 Casey Albert Wood.



Wood, born in Ontario, Canada in 1856, first studied medicine in Montreal with further studies at Berlin, Vienna, Paris and London where he worked at Moorfields. He studied in Montreal under William (later Sir William) Osler and it was at this early stage that his passion for ophthalmology began. Before then however, even from childhood, his second passion, for nature study and particularly ornithology, took root. Together ophthalmology and ornithology would guide Wood through his life. Having no children, he, his wife Emma and their pet parrot John Paul toured the globe after his retirement in 1906, collecting material for his magnum opus on the appearance of the avian retina, published in 1917 (Figure [2.2](#)). This was not just a work arising from a general interest in birds. Wood considered that the superior optics and visual capability of many birds when compared with the human eye may well lead to discoveries which would improve human vision.

[Figure 2.2](#) The tawny owl retina from *The Fundus Oculi of Birds*, 1917.



But while *The Fundus Oculi of Birds* is the book for which Wood is remembered today, he was a key general ophthalmologist in North America at the end of the nineteenth century, one might even argue the key ophthalmologist. His 1896 publication implicating methyl alcohol in the etiology of toxic amblyopia was considered a classic work, and Wood was editor at various times of the *Ophthalmic Record*, the *Annals of Ophthalmology*, and the *American Journal of Ophthalmology* (of which he was a founder in 1884). He wrote of *A System of Ophthalmic Therapeutics* (1909), *A System of Ophthalmic Operations* (1911), and the seventeen-volume *American Encyclopedia of Ophthalmology* (1914–1920). But more than that, Wood was fascinated by the history of ophthalmology and, of course, by comparative ophthalmology. Wood translated numerous historical ophthalmic texts from all over the world into English. A masterpiece is his translation of the earliest printed book on ophthalmology, *De Oculis Eorumque Egritudinibus et Curis*, written by the twelfth-century physician, Benvenuto Grassi, and first published in Ferrara in 1474.

For most of his working life Casey Wood was an ophthalmologist in Chicago, joining the faculty in 1899 and becoming Head of Ophthalmology in 1913, when the College of Physicians and Surgeons of Chicago became the

University of Illinois College of Medicine and holding that position until 1917. He was described as 'one of the most colorful and outstanding figures in ophthalmology at the turn of the century, not only in Chicago but nationally and internationally as well.' In 1929 Wood organized the ornithological titles at the British Museum and prepared its first catalogue describing that collection. Travelling widely in pursuit of this interest, he collected specimens in British Guiana, the Caribbean, the South Pacific, India, Ceylon, Australia and New Zealand. Wood retired from the College in 1925, spending much of his last decade at the Vatican Library in the translation of medieval European and Arabic ophthalmic manuscripts.

It has to be said that from a political perspective Wood held some views with which we might not agree - he was an ardent fascist, supporting Mussolini in the 1930s while he worked in Europe towards the end of his life, but had progressive views on the importance of animal experimentation held in balance with animal welfare. These opinions stemmed from his interest both in human medicine and also in environmental conservation, developed in his early childhood in the fields around his home in Ontario.

Another important ophthalmologist of the turn of the twentieth century with an abiding passion for comparative ophthalmology was George Lindsay Johnson (Figure [2.3](#)). Born in 1853 and dying in 1943, Johnson was almost exactly Wood's contemporary. Interestingly, while Wood spent a formative period of his professional life in Germany, Johnson's early education occurred there although he had been born in Manchester. He was in Strasbourg in 1870 when the Prussians seized the city in a devastating episode in the Franco-Prussian war. Escaping from the beleaguered city, he spent a year on a relative's ranch in Australia before returning to his roots and studying at Owen's College in Manchester. He then undertook his undergraduate degree at

Caius College in Cambridge and St Bartholomew's Hospital in London, becoming a Fellow of the Royal College of Surgeons in 1884 and taking his MD from Cambridge in 1890. His ophthalmic career began as a registrar at the Royal Westminster Hospital in London followed by a period at the Royal Eye Hospital in Southwark, London.


Figure 2.3 George Lindsay Johnson.

Reproduced with permission from Elsevier.



During this period in London, he spent much of his spare time at the Zoological Society of London performing ophthalmic observations on a wide variety of species; this resulted in papers in the Philosophical Transactions of the Royal Society of London first on the comparative ophthalmoscopy of the mammalian eye and secondly a sequel on the eyes of reptiles and amphibians (Figure [2.4](#)).

Figure 2.4 The fundus of the elephant from Johnson's 1902 monograph.



In this he was ably assisted by Arthur Head, ophthalmic artist of no mean distinction, as may be observed looking at his illustrations of the fundus of species from tigers to rattlesnakes (Figure [2.5](#)). Head was also responsible for the illustrations in Wood's *The Fundus Oculi of Birds*, most of which were also undertaken in painstaking hours in the Zoological Collection at Regent's Park.

[Figure 2.5](#) Arthur Head examining the fundus of a lion.



Between these two ophthalmologists of a century ago and Duke Elder stand two further key figures in the subject of comparative ocular biology. These are the French ophthalmologist, Andre Jean Francois Rochon-Duvigneaud, and the American, Gordon Walls. Rochon-Duvigneaud (Figure [2.6](#)) will be remembered for his comment that a raptor was 'a wing guided by an eye' but had considerably wider comparative interests, documented in his book *Les Yeux et la Vision des Vertebres* of 1943 [1]. But his studies ranged far wider than merely the avian eye. Born in 1863 he

studied medicine in the Faculte de Bordeaux and later in Paris writing a seminal doctoral thesis on the anatomy of the human iridocorneal angle in 1892. His studies took him from the human eye to a more comparative approach and, in 1926, rather in the same way Wood had done ten years earlier, he retired from clinical practice to devote his time to comparative ophthalmology. He was the first to recognise recessively inherited glaucoma with buphthalmos in the New Zealand White rabbit as far back as 1921 [2] although in human ophthalmology he is more commonly associated with the syndrome resulting from traumatic collapse of the superior orbital fissure with damage to the nerves passing through it, which bears his name [3].

Figure 2.6 Andre Rochon-Duvigneaud.

Reproduced with permission from Elsevier.



Gordon Walls (Figure [2.7](#)) was the only one of our comparative ophthalmic investigators who was not first a human ophthalmologist. He published a number of papers and monographs in comparative ophthalmology but is primarily remembered for his masterpiece *The Vertebrate Eye and its Adaptive Radiation* [4] which was published a year earlier than Rochon-Duvigneaud's text. Walls was

originally an engineer, moving into zoology in Harvard where he undertook work on the ultrastructure of the retina across the vertebrates. Study of the reptile eye in particular allowed him to formulate many of his ideas on the evolution of the vertebrate photoreceptor but as his magnum opus shows, his interest in development of the eye through evolution ranged across its whole anatomy and physiology, his life's work finishing with study of the intricacies of comparative colour vision on the one hand and of the evolution of ocular movement and extraocular muscle action on the other.

Figure 2.7 Gordon Walls.



In the last half century and more since the deaths of Wood, Johnson, Rochon-Duvigneaud and Walls, the subject of visual ecology has become a recognised discipline, with researchers correlating visual function with behaviour of species in the wild from the visual capabilities of deep sea fish to the hunting behaviour of birds of prey. Several books on the subject are worthy of perusal. Here we add a paragraph or two on visual function in the species discussed before detailing the diseases seen in these animals. Clearly in such a limited compass detailed evaluation is not possible and thus the reader is directed to the works of Ron Douglas

[5], Michael Land and Dan-Eric Nilson [6], Ivan Schwab [7] and Chris Murphy [8].

References

1. The avian portion of the work is available online at <http://www.theavianeye.com/translated>.
2. Rochon-Duvigneaud A. Un cas de buphtalmie chez le lapin: etude anatomique et physiologique. *Ann Oculist (Paris)* 1921;158:401-414.
3. Rochon-Duvigneaud A. Quelques cas de paralysie de tous les nerfs orbitaires (ophthalmoplegie totale avec amaurose en anesthésie dans le domaine de l'ophtalmique d'origine syphilitique). *Archives D'ophtalmologie (Paris)* 1896;16:746-760.
4. Walls GL. *The Vertebrate Eye and its Adaptive Radiation*. Bloomfield Hills, MI: The Cranbrook Institute of Science, 1942.
5. Douglas RH, Djamgoz MBA. *The Visual System of Fish*. London: Chapman and Clarke, 1990.
6. Land MF, Nilsson D-E. *Animal Eyes*. Oxford: Oxford University Press, 2002.
7. Schwab IR. From eye spots to eye shine. *Br J Ophthalmol* 2000;84:1214. (The first in a wonderful series of annotated cover illustrations ranging across the field of ocular evolution. Schwab's masterpiece *Evolution's Witness: How Eyes Evolved* (Oxford University Press, 2011) is a 'must-read')
8. Murphy CJ, Kern TJ, Howland HC. Refractive state, corneal curvature, accommodative range and ocular anatomy of the Asian elephant (*Elephas maximus*). *Vision Research* 1992;32:2013-2021. (One of a number of papers on the refractive status of a wide range of non-domestic species.)

Chapter 3

Common features of exotic animal ophthalmology

We will discuss the ocular anatomy and physiology of different species groups at the beginning of each chapter together with an assessment of how and what the different species actually see. Here we consider some areas which unite the different types of animal eye, before moving on to examine fish, amphibians, reptiles, birds and mammal species individually in detail.

Ocular Examination

The similarity between eyes of different species means that the basic techniques of ocular examination can be extrapolated from those of dogs and cats. The differences generally occur because of the small size of many eyes of exotic animal species, be they rodents, caged birds or reptiles.

From one perspective a direct ophthalmoscope can be used whatever the size of the globe. And yet the ease of examination and the quality of retinal image is indeed reduced with a pupil of 2 or 3 mm compared with the dilated dog or cat pupil at nearly 10 mm in diameter.

Whether used on a small rodent or a large dog, the direct ophthalmoscope can be used at 0 dioptres (D) as the cornea and lens refract the incoming light on to the retina whatever the size of the globe. Similarly using the direct ophthalmoscope at +10 D focuses light on the lens and iris

and at +20 D the cornea can be seen at high magnification (Figure [3.1](#)). It has to be said that most veterinary ophthalmologists who regularly examine rodents use the indirect technique and a +30 D lens to examine the eye [1]. But the technique one learns while training tends to stick and Dr Keith Barnett who inspired me and taught me all I know about veterinary ophthalmology always used the direct ophthalmoscope, so that is what I feel most familiar with. Professor Peter Bedford, with whom I worked later in my ophthalmic training, never seemed to pick up a direct, always using the binocular indirect for examination of the retina using the loupe lens at a distance (Figure [3.2](#)) and the lens and cornea at a shorter distance from the eye (Figure [3.3](#)).

[Figure 3.1](#) Using the direct ophthalmoscope to examine a rabbit eye.



[Figure 3.2](#) Using an indirect ophthalmoscope to examine the fundus of an owl eye.

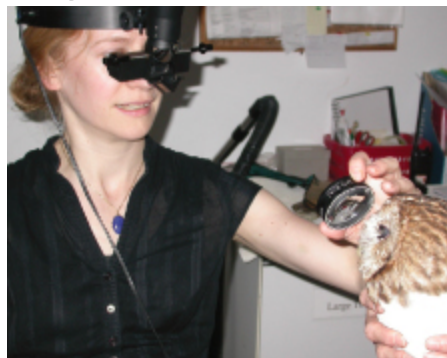
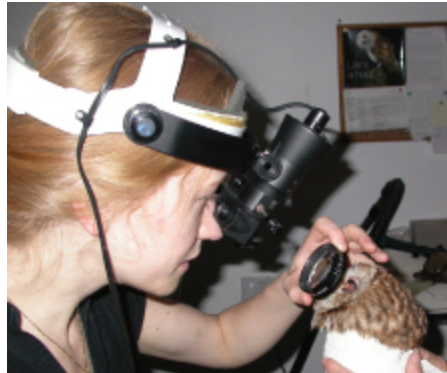

Figure 3.3 Using the indirect ophthalmoscope to examine the anterior segment of an owl eye.



Using a +30 D or even a higher dioptré lens can give a significantly wider view of the retina than a direct ophthalmoscope but is quite a difficult technique to master. It requires as dilated a pupil as possible, which brings us on to another problem with a number of exotic species, that of mydriasis. A novel and useful technique recent published for rodent fundus imaging and photography, a notoriously taxing exercise, is the use of a video endoscope [2].

The small size of the eye means that the slit lamp with its high magnification is very useful in many of these species (Figure 3.4) [3]. Although, as its name suggests, this instrument is optimally used with a slit beam of light creating an optic cross-section of the ocular tissues observed, most of the time veterinary ophthalmologists use it with a full beam of light as a binocular magnifying system, especially where the small eyes of most exotic pet species are concerned.

Figure 3.4 Using a slit lamp biomicroscope to examine the anterior segment of the eye.