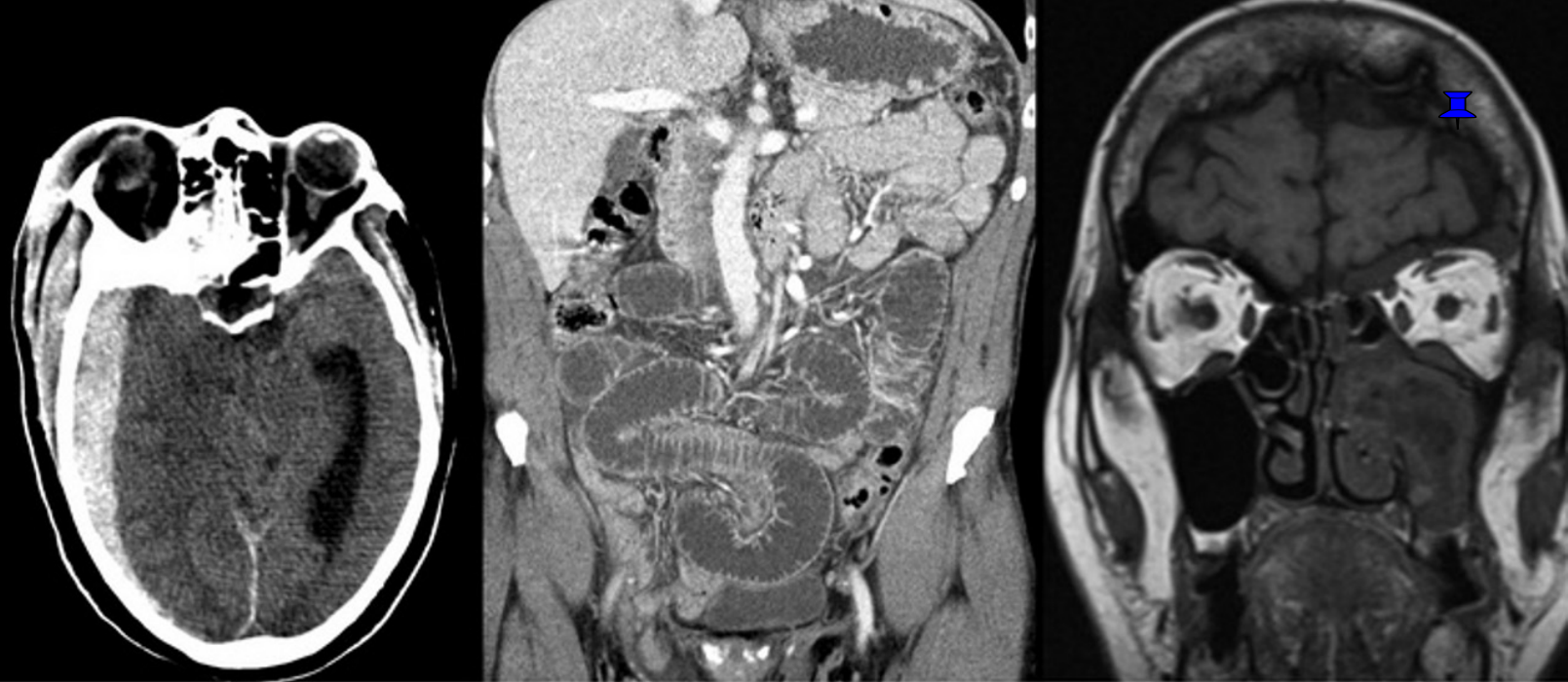

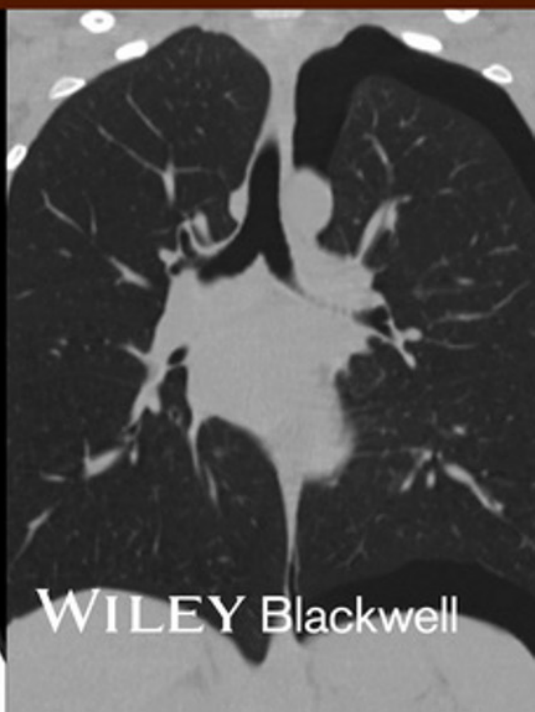

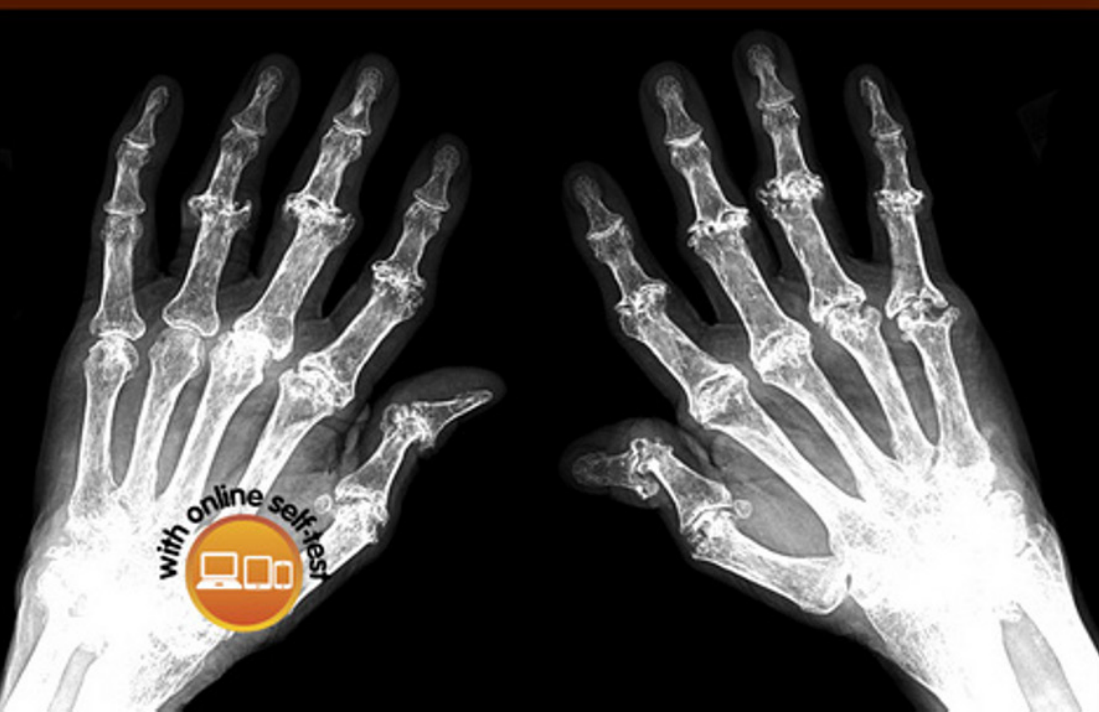
Critical Observations in Radiology

for Medical Students

Edited by

Katherine R Birchard | Kiran Reddy Busireddy | Richard C Semelka



WILEY Blackwell

Critical Observations in Radiology for Medical Students

Critical Observations in Radiology for Medical Students

Katherine R. Birchard, MD

Assistant Professor of Radiology, Cardiothoracic Imaging
Department of Radiology
University of North Carolina
Chapel Hill
USA

Kiran Reddy Busireddy, MD

Department of Radiology
University of North Carolina
Chapel Hill
USA

Richard C. Semelka, MD

Professor of Radiology, Director of Magnetic Resonance Imaging, Vice Chair of Quality and Safety
Department of Radiology
University of North Carolina
Chapel Hill
USA

WILEY Blackwell

This edition first published 2015 © 2015 by John Wiley & Sons, Ltd

Registered Office

John Wiley & Sons, Ltd, The Atrium, Southern Gate, Chichester, West Sussex, PO19 8SQ, UK

Editorial Offices

9600 Garsington Road, Oxford, OX4 2DQ, UK

The Atrium, Southern Gate, Chichester, West Sussex, PO19 8SQ, UK

350 Main Street, Malden, MA 02148-5020, USA

For details of our global editorial offices, for customer services and for information about how to apply for permission to reuse the copyright material in this book please see our website at www.wiley.com/wiley-blackwell

The right of the authors to be identified as the authors of this work has been asserted in accordance with the UK Copyright, Designs and Patents Act 1988.

All rights reserved. No part of this publication may be reproduced, stored in a retrieval system, or transmitted, in any form or by any means, electronic, mechanical, photocopying, recording or otherwise, except as permitted by the UK Copyright, Designs and Patents Act 1988, without the prior permission of the publisher.

Designations used by companies to distinguish their products are often claimed as trademarks. All brand names and product names used in this book are trade names, service marks, trademarks or registered trademarks of their respective owners. The publisher is not associated with any product or vendor mentioned in this book. It is sold on the understanding that the publisher is not engaged in rendering professional services. If professional advice or other expert assistance is required, the services of a competent professional should be sought.

The contents of this work are intended to further general scientific research, understanding, and discussion only and are not intended and should not be relied upon as recommending or promoting a specific method, diagnosis, or treatment by health science practitioners for any particular patient. The publisher and the author make no representations or warranties with respect to the accuracy or completeness of the contents of this work and specifically disclaim all warranties, including without limitation any implied warranties of fitness for a particular purpose. In view of ongoing research, equipment modifications, changes in governmental regulations, and the constant flow of information relating to the use of medicines, equipment, and devices, the reader is urged to review and evaluate the information provided in the package insert or instructions for each medicine, equipment, or device for, among other things, any changes in the instructions or indication of usage and for added warnings and precautions. Readers should consult with a specialist where appropriate. The fact that an organization or Website is referred to in this work as a citation and/or a potential source of further information does not mean that the author or the publisher endorses the information the organization or Website may provide or recommendations it may make. Further, readers should be aware that Internet Websites listed in this work may have changed or disappeared between when this work was written and when it is read. No warranty may be created or extended by any promotional statements for this work. Neither the publisher nor the author shall be liable for any damages arising herefrom.

Library of Congress Cataloging-in-Publication Data

Critical observations in radiology for medical students / [edited by] Katherine R. Birchard, Kiran Reddy Busireddy, Richard C. Semelka. p. ; cm.

Includes bibliographical references and index.

ISBN 978-1-118-90471-8 (pbk.)

I. Birchard, Katherine R., 1973–, editor. II. Busireddy, Kiran Reddy, 1983–, editor. III. Semelka, Richard C., editor.

[DNLM: 1. Radiography. 2. Diagnostic Imaging. WN 200]

RC78.4

616.07/572–dc23

2014047515

A catalogue record for this book is available from the British Library.

Wiley also publishes its books in a variety of electronic formats. Some content that appears in print may not be available in electronic books.

Cover images: Axial CT image showing acute right temporal subdural hematoma; coronal contrast enhanced image of the abdomen and pelvis demonstrating long-segment small bowel dilatation; coronal T1 image showing left acute invasive sinusitis; PA radiograph image of both hands showing rheumatoid arthritis; coronal CT image in lung window setting showing left pneumothorax. Images by Katharine R. Birchard, Kiran Reddy Busireddy and Richard C. Semelka.

Set in 9/11pt Minion by SPi Publisher Services, Pondicherry, India

Contents

Contributors, vi

Preface, vii

About the companion website, viii

- 1** Basic principles of radiologic modalities, 1
Mamdoh AlObaidy, Kiran Reddy Busireddy, and Richard C. Semelka
- 2** Imaging studies: What study and when to order?, 10
Kiran Reddy Busireddy, Miguel Ramalho, and Mamdoh AlObaidy
- 3** Chest imaging, 27
Saowanee Srirattanapong and Katherine R. Birchard
- 4** Cardiac imaging, 49
Nicole T. Tran and J. Larry Klein
- 5** Abdominopelvic imaging, 65
Pinakpani Roy and Lauren M.B. Burke
- 6** Brain imaging, 96
Joana N. Ramalho and Mauricio Castillo
- 7** Spine imaging, 116
Joana N. Ramalho and Mauricio Castillo
- 8** Head and neck imaging, 136
Joana N. Ramalho, Kiran Reddy Busireddy, and Benjamin Huang
- 9** Musculoskeletal imaging, 163
Daniel B. Nissman, Frank W. Shields IV, and Matthew S. Chin
- 10** Breast imaging, 201
Susan Ormsbee Holley
- 11** Pediatric imaging, 213
Cassandra M. Sams
- 12** Interventional Radiology, 235
Ari J. Isaacson, Sarah Thomas, J.T. Cardella, and Lauren M.B. Burke

Index, 253

Contributors

Mamdoh AIObaidy, MD

Department of Radiology
University of North Carolina
Chapel Hill
USA

Katherine R. Birchard, MD

Assistant Professor of Radiology
Cardiothoracic Imaging
Department of Radiology
University of North Carolina
Chapel Hill
USA

Lauren M.B. Burke, MD

Assistant Professor of Radiology
Division of Abdominal Imaging
Department of Radiology
University of North Carolina
Chapel Hill
USA

Kiran Reddy Busireddy, MD

Department of Radiology
University of North Carolina
Chapel Hill
USA

J.T. Cardella, MD

University of North Carolina
Chapel Hill
USA

Mauricio Castillo, MD, FACR

Professor and Chief of Neuroradiology
Department of Radiology
University of North Carolina
Chapel Hill
USA

Matthew S. Chin, MD

Department of Radiology
University of North Carolina
Chapel Hill
USA

Susan Ormsbee Holley, MD, PhD

Assistant Professor of Radiology
Breast Imaging Section, Mallinckrodt Institute of
Radiology
Washington University School of Medicine
St. Louis, MO
USA

Benjamin Huang

Assistant Professor of Radiology, Neuroradiology
Department of Radiology
University of North Carolina
Chapel Hill
USA

Ari J. Isaacson, MD

Assistant Professor of Radiology
University of North Carolina
Chapel Hill
USA

J. Larry Klein, MD

Clinical Professor of Medicine and Radiology
University of North Carolina
Chapel Hill
USA

Daniel B. Nissman,

MD, MPH, MSEE

Assistant Professor of Radiology
Musculoskeletal Imaging, Department of Radiology
University of North Carolina
Chapel Hill
USA

Joana N. Ramalho, MD

Department of Neuroradiology
Centro Hospitalar de Lisboa Central
Lisboa
Portugal
Department of Radiology
University of North Carolina
Chapel Hill
USA

Miguel Ramalho, MD

Research Instructor
Department of Radiology
University of North Carolina
Chapel Hill
USA

Pinakpani Roy, MD

Radiology Resident
Department of Radiology
University of North Carolina
Chapel Hill
USA

Cassandra M. Sams, MD

Department of Radiology
University of North Carolina
Chapel Hill
USA

Saowanee Srirattanapong, MD

Instructor
Department of Diagnostic and Therapeutic Radiology
Faculty of Medicine Ramathibodi Hospital
Mahidol University
Bangkok, Thailand

Richard C. Semelka, MD

Professor of Radiology; Director of Magnetic
Resonance Imaging; Vice Chair of Quality and Safety
Department of Radiology
University of North Carolina
Chapel Hill
USA

Frank W. Shields IV, MD

Clinical Fellow
Department of Radiology
University of North Carolina
Chapel Hill
USA

Sarah Thomas

Clinical Fellow
University of North Carolina
Chapel Hill
USA

Nicole T. Tran, MD

Assistant Professor of Medicine
Department of Cardiology
University of Oklahoma
Norman, USA

Preface

The intention of this textbook is to provide medical students with a concise description of what is essential to know in the vast field of modern Radiology, hence the expression 'critical observations'. More and more in the modern age of health care, imaging studies occupy a central role in the management, and progressively also the treatment, of patients. It is important that our future doctors have a good, broad understanding of modern Radiology practice, which this book provides. Rather than rehashing old

information from old text-books, which typically happens with texts designed for students, we have taken a fresh look at imaging providing state-of-the-art descriptions, discussions and images.

Katherine R. Birchard
Kiran Reddy Busireddy
Richard C. Semelka

About the companion website

Don't forget to visit the companion website for this book:

www.wiley.com/go/birchard



There you will find valuable material designed to enhance your learning, including:

- Interactive multiple choice questions
- Downloadable images and algorithms from the book

Scan this QR code to visit the companion website:



CHAPTER 1

Basic principles of radiologic modalities

Mamdoh AIObaidy, Kiran Reddy Busireddy, and Richard C. Semelka

Department of Radiology, University of North Carolina, Chapel Hill, USA

Introduction

In this chapter, we will describe the features and basic imaging principles of the various modalities employed in radiology. Since many specialties perform these types of studies, “radiology” is often also referred to generically as “imaging.” A basic feature of all imaging is that pictures are generated, and the quality of the pictures oftentimes depends on how pathologies stand out compared to normal tissues.

Each of the different modalities uses their own terms to describe pathology, which relate back to how the images themselves are created. In this chapter, brief technical descriptions of each modality will be discussed with special emphasis on image production, image description, factors that influence image quality, and associated imaging artifacts with each modality.

X-ray-based imaging modalities

Plain radiography, mammography, fluoroscopy, and computed tomography (CT) all use X-rays as the source of generating images. All these modalities employ an X-ray tube to generate the images. The controllable factors are tube voltage, measured in kVp; tube current, measured in mA; and total exposure time, measured in seconds.

The X-ray tubes produce X-rays by accelerating electrons to high energies from a filament (cathode) to a tungsten target (anode) by heating the filaments to a very high temperature, which then emits electrons. The flow of electrons from the filament to the target constitutes the tube current (mA). X-rays are produced when energetic electrons strike the target material; electron kinetic energy is transformed into heat and X-rays, which are then filtrated at the X-ray tube window to achieve higher beam quality. The term mAs refers to the product of tube current and time duration.

These X-rays are then directed to the imaged subject (the patient). The number of X-rays produced by the X-ray beam is related to the X-ray beam intensity, measured in terms of air kerma (mGy). X-ray beam intensity (mA) is proportional to the X-ray tube

current. X-ray beam intensity is also proportional to the exposure time, which is the total time during which a beam current flows across the X-ray tube. Doubling the tube current, the number of X-rays or the exposure time will double the X-ray beam intensity, but will not affect the average energy of the beam. KVp affects the penetrating power of X-rays and hence tissue contrast.

Image production can be achieved using analog or digital systems. Analog radiography uses films to capture, display, and store radiographic images. Digital systems can be classified as cassette and noncassette systems.

Plain radiography (X-rays)

Image production

X-ray tube voltage varies according to imaged body part. Exposure times range between tens and hundreds of milliseconds.

The typical settings to obtain an erect posteroanterior chest radiograph are a kVp of 100 and mAs of 4. The typical settings to obtain an erect anteroposterior abdominal radiograph are a kVp of 80 and mAs of 40. The typical kVp and mAs settings for imaging the appendicular skeleton are 52–60 and 2.5–8, respectively. Note that there are slight variations between the kVp and mAs for these different regions. This reflects that more current is needed to penetrate regions with more tissue (abdomen compared to chest), and optimal contrast is different to study the disease processes of these different regions as well (abdomen compared to skeleton).

Image descriptors

The most common projections in plain radiography are frontal (anteroposterior or posteroanterior), lateral, oblique, or cross-table, based on the direction of X-ray beam in relation to the patient. Special positions and projections are used in musculoskeletal (MSK) imaging.

Frontal projection images are interpreted as if the patient is sitting in front of the reader; where the left side of the image corresponds to the right side of the patient.

The brightness of a structure on plain radiography is related to its atomic number; structures containing material with higher atomic number absorb more photons before they reach the detector or film. In plain radiography, bright areas are described as radiopaque or radiopacity, and dark areas are described as radiolucent. Metals, bones, some stones, contrast materials, and various pathologies appear as radiopaque. Air/gas appears as radiolucent.

Image performance

X-ray-based imaging modalities including plain radiography, mammography, fluoroscopy, and CT share the same parameters that can influence image quality. Combinations of tube voltage, tube current, and exposure time, and focal spot size govern the final image quality.

Optimization of these parameters to achieve a diagnostic quality image with minimum radiation is the principal goal. Plain radiographic studies generally offer the highest spatial resolution, with the subcategory of mammography having the very highest, followed by CT, magnetic resonance imaging (MRI), and then nuclear medicine.

Mammography

Mammography is an X-ray-based imaging modality that uses low-energy X-rays to image the breasts as a diagnostic and screening tool.

Image production

X-ray tubes in mammography units used molybdenum as a target and a much smaller focal spots. The tube voltage in mammography ranges from 25 to 34 kV. The heel effect, described as higher X-ray intensity on the cathode side, is utilized in mammography to increase the intensity, that is, penetration, of radiation near the chest wall where tissue thickness is relatively greater.

Compression is used in mammography to reduce the breast parenchymal thickness, which achieves immobilization and reduction in radiation dose, thereby decreasing blurring and increasing sharpness.

Digital tomosynthesis mammography is a newer form of mammography that offers high resolution and is performed using limited-angle tomography (multiple projections at different angles) at mammographic dose levels. The acquired data set is reconstructed using iterative algorithms.

Stereotaxic localization is achieved by acquiring two images, each 15° from the normal projection. This technique provides good localization of masses and is used to perform core needle biopsies.

Image descriptors

The two routinely used mammography views are craniocaudal (CC) and mediolateral oblique (MLO). Other additional views include true lateral, exaggerated, axillary, and cleavage views. Compression views can also be acquired in cases of where the presence of a tumor is uncertain and to resolve any possible parenchymal overlap.

Images are usually reviewed in pairs to help assess for any asymmetry. Mammographic findings are usually described using the terminology of Breast Imaging Reporting and Data System (BI-RADS) lexicon, which includes the description of breast parenchyma, masses, calcifications, and distortion, followed by the assignment of a BI-RADS score, which is used for patient management and to determine follow-up intervals.

Fluoroscopy

Fluoroscopy is an X-ray-based imaging technique commonly used to obtain real-time images of the internal structures of a patient through the use of a fluoroscope.

Image production

Fluoroscopy units are composed of X-ray generator, X-ray tube, collimator, filters, patient table, grid, image intensifier, optical coupling, television system, and image recording. Fluoroscopy units operate using low tube currents (1–6 mA) and tube voltages (70–125 kV). When the X-ray beam is switched off, last image hold (LIH) software permits the visualization of the last image. Newer fluoroscopy systems use pulsed fluoroscopy to reduce dose by acquiring frames that are less than real time (quarter to half the number of frames per second).

Fluoroscopy systems use a television camera to view the image output of the image intensifiers by converting light images into electric (video) signals that can be recorded or viewed on a monitor. Fluoroscopy allows real-time observation and imaging of dynamic activities. It has many applications in radiology, including gastrointestinal (GI), genitourinary, cardiovascular, neuromuscular, and MSK procedures. It can be used for diagnostic and interventional procedures, whether in the fluoroscopy, cardiology, endoscopy, and interventional suites as well as in the operating room.

Cineradiography refers to real-time visualization of motion with fluoroscopy, and frame rate varies from very fast (30 frames/s) in vascular studies during injection of contrast injection to slower to observe motility of the GI tract.

Digital subtraction angiography (DSA) is a fluoroscopic technique used for imaging the vascular system following intravascular contrast injection. In this technique, subtracting the acquired non-contrast mask image, from subsequent frames following contrast administration, allows the removal of static nonenhancing vascular structures that augments visualization of even the smallest contrast differences. This permits using a much lower intravenous (IV) contrast dose. The mean rate of flow of iodine contrast through a vessel can be determined; the extent of vessel stenosis and the pressure gradients may also be estimated.

Road mapping permits an image to be captured and displayed on a monitor while a second monitor shows live images, which is primarily utilized in vascular applications.

Image descriptors

Fluoroscopy uses the same projections and image descriptions used in plain radiography. Oblique views are extensively used in real time fluoroscopy to detect structures or abnormalities, and the position is described in relation of the beam to the patient and patient orientation to the imaging table. Examples of these views include right anterior oblique, left anterior oblique, and right posterior oblique.

CT

CT is a modality that uses computer-processed X-rays to produce axial, cross-sectional “tomographic” images, allowing for excellent imaging with great anatomical details.

Image production

A CT X-ray tube produces a fan-shaped X-ray beam, which passes through the patient, and is measured by the array of detectors on the opposite side of the patient, the sum of which is referred to as a projection. A number of projections are used for each tube rotation.

The sum of projections is plotted as a sinogram, which is then converted to CT images by a mathematical analysis process using filtered back-projection image reconstruction algorithms and applying different types of filters depending on the clinical indication and structure of interest. The factors adjusted by the CT scan operators are the X-ray tube voltage, current, field of view, collimation, slice thickness, and pitch.

CT scanners have gone through revolutionary changes in the last four decades. The generation of systems that is the most common in current use is the third-generation CT machines. These utilize a wide fan beam and a large array of detectors, which rotate around the patient.

Most modern CT scanners also have multiple rows of detectors, typically between 4 and 64, with the more current systems having a greater number of rows. These multidetector CT (MDCT) systems permit larger anatomical coverage in a shorter time frame.

In helical acquisition mode (also known as spiral CT), the table continuously moves while the X-ray tube rotates around the patient until the desired anatomic area is scanned. This is the most common form of CT acquisition in CT studies.

CT fluoroscopy utilizes continuous X-ray tube rotation with very low tube currents (15–60 mA) to obtain a near-real-time image reconstruction. This technique is primarily used to aid interventional procedures, like fine needle aspiration, biopsies, or drainage procedures.

Dual-energy CT (DECT) employs utilization of two different energies (80 and 140 kVp). This optimizes the detection of substances that have greatly different X-ray absorptions (densities). This technique offers various advantages including improved temporal resolution (as short as 83 ms), improved tissue characterization, ability to generate virtual nonenhanced data sets, improved subtraction of bones, pulmonary ventilation and perfusion imaging, and improved detection of iodine-containing substances on low-energy images.

Image descriptors

All CT examinations begin with acquisition of two projection radiograph (frontal and lateral), referred to as topographic or scout images.

Newer MDCT scanners use volumetric data acquisition in the axial plane with slice thickness of 0.625 mm, which can then be reconstructed into slice thickness of 3–5 mm, which are then submitted to PACS or printed on films (hard copies).

The original data set can be reformatted into coronal or sagittal reformats. They can also be postprocessed on dedicated workstation for multiplanar reformation (MPR), maximal intensity projection (MIP) imaging, minimal intensity projection (MinIP) imaging, and volume rendering (VR) imaging.

CT images are composed of maps of the relative attenuation values of the imaged tissues (4096 gray levels), expressed as CT numbers or Hounsfield units (HU). HU value of zero is by default assigned to water. These values are approximate values that can be used to characterize tissues.

CT images are viewed as if the patient is being looked at from below, where the left side of the image corresponds to the right side of the patient and vice versa. The terms “density” and “attenuation” are used to semiquantify tissues where bright structures are described as hyperdense or high attenuating and darker structures are described as hypodense or low attenuating.

Artifacts

Artifacts in CT imaging can be related to mechanical malfunction or related to patients. The most common artifact is motion artifact that is generally secondary to bulk patient motion or organ motion

(e.g., heartbeat, breathing). Motion artifact is becoming less of a problem with the advent of newer MDCT machines that acquire images with faster acquisition.

One of the most important artifacts is streak artifact, which is encountered when imaging high-density structures, such as metallic implants, dental fillings, surgical clips, or dense contrasts within the GI tract. This creates a starburst effect of radiating bright lines, which can lead to significant image degradation.

Another common artifact is volume averaging, which arises when structures that are adjacent to each other along the long axis of the patient appear as if they are of the same entity or that they arise from the same entity. This occurs as a function of slice thickness; the thicker the slices, the more likely this effect will be observed.

Ultrasound

Ultrasound (US) is a nonionizing imaging modality that utilizes US waves to provide imaging of anatomical structures with excellent spatial resolution and to study vascular flow dynamics.

Image production

US is a widely available, compact, portable, and relatively inexpensive modality capable of providing real-time imaging. It does not use any ionizing radiation and has no known long-term side effects. Additionally, US Doppler/duplex allows for quantitative measurement of absolute blood velocity. US can be used for diagnostic and interventional procedures.

US probes contain a specific type of crystals, made from specialized materials, which convert voltage oscillations to US waves by changing shape and pressure (piezoelectric effect). Gel is always applied between the transducer and skin to displace air, permitting better transducer–skin contact to minimize interference with US transmission into the patient. After the US beam interacts with soft tissue, the reflected beam is received by the probe crystals, and the crystals record the change in pressure of the reflected beam. This is then converted back to electrical current, which is then processed by the computer board to produce an image.

There are different types of transducers, including linear, curved, and sector transducers, which also have variable frequencies. US transducers are commonly used on the skin surface for scanning. However, endoluminal techniques obviate many of the problems of surface scanning and include endovaginal, endorectal, endointestinal, and endovascular.

US images can be displayed by a variety of methods. The most commonly used mode is the brightness (B) mode, which can be seen as shades of gray, which offers real-time imaging with a high frame rate.

Color Doppler is used to display moving red blood cells (RBCs) according to their direction of flow in reference to the US probe. Power Doppler is a variation of this method, which has better sensitivity for detecting moving objects, but without the ability to assess the direction of flow.

Duplex scanning combines real-time B mode imaging with Doppler imaging. Spectral analysis displays frequency shift as a function of time that can provide information regarding blood flow pulsatility, direction, and absolute flow velocity (quantitative evaluation).

US can also be used intraoperatively by applying a transducer with a sterile probe cover or sheath in direct contact with the organ being examined. It can also be used to guide interventional procedures, such as biopsies, drainages, or tube placement.

High-intensity focused ultrasound (HIFU) is used as a hyperthermia therapy, a class of clinical therapies that use temperature to treat diseases. Clinical HIFU procedures are typically performed in conjunction with an imaging study, an example of which is HIFU treatment of uterine fibroids localized with MRI.

Image descriptors

The interpretation of US images relies on recognizing anatomical relationships and level of pixel brightness, the latter referred to as echogenicity.

Structures are described according to their echogenicity compared to adjacent structures as hypoechoic (low), hyperechoic (high), isoechoic (similar), or anechoic (almost no reflection).

The direction of flow is described according to the direction of the flow as toward (red) or away (blue) from the US probe on color Doppler and as toward (above) or away (below) from the baseline on spectral Doppler images. Images are described based on the orientation of the probe in relation to the human body as longitudinal, when the axis of the probe is parallel to the body, or axial, when the axis of the probe is perpendicular to the body.

Image performance

The quality of the US image is based on resolution, which can be divided into axial, lateral, and elevational resolution. Axial resolution is the ability to separate two objects lying along the axis of the beam and is determined by the US probe frequency. Lateral resolution is approximately four times worse than axial resolution, and it decreases at a longer distance from the probe. Elevational resolution is equivalent to slice thickness and is proportional to US probe width.

Artifacts

Artifacts in US imaging are very common and should be recognized to avoid diagnostic errors. Some artifacts can be utilized to enhance diagnostic performance such as acoustic shadowing, acoustic enhancement, aliasing, twinkle, and ring-down artifacts. Some artifacts however negatively impact diagnostic performance such as mirror image and side-lobe artifact.

MRI

MRI is a nonionizing imaging modality that uses the body's natural magnetic properties (imaging of protons) to produce detailed images with excellent anatomical details and exquisite, unmatched soft tissue contrast images from any part of the body.

Image production

Hydrogen nuclei have the largest nuclear magnetization, and these occur abundantly in humans in the form of water, which contains two hydrogen molecules (protons), and fat, which contains multiple protons. In the absence of an applied magnetic field, these hydrogen protons are randomly aligned with no net magnetization.

MRI machines are based on powerful magnets, which can generate a strong and stable magnetic field. The magnetic field strength is measured in tesla (T). The magnets used may be resistive, permanent, or superconducting. The vast majority of current magnetic resonance (MR) scanners use superconducting magnets, which contain a wire-wrapped cylinder and a constantly circulating electric current of hundreds of amps to generate the uniform magnetic field. The encircling wire that forms the magnetic core is composed of specialized material that must be kept very cold (using liquid helium as a refrigerant), in order that the electrons flowing in

the wire experience extremely low friction or impedance. This permits creation of a very powerful current that generates a strong magnetic field strength, a process termed superconduction.

Unlike most other imaging modalities (such as CT and US) that are only "on" when the patient is being imaged, the MR system magnet is always "on." This explains why with MRI health-care professionals have to be very careful not to bring ferromagnetic (iron-containing) objects into the MR room that can be drawn into the magnet at high velocity giving a missile effect, which can lead to injury of the patients and personnel, as well as cause unnecessary downtime of the MR system.

Other essential components of an MRI system are three gradient coils, which are used to code the spatial location of the MR signal by superimposing a linear gradient on the main magnetic field (this causes protons at different locations to have different precession frequencies), and the radiofrequency (RF) coils, which consist of various configurations of radio wave antenna and are used to transmit and receive electromagnetic radio waves. There are different coils including volume coils, specialized coils, and surface coils. Phased array coils are a combination of many surface coils (elements) and are required for parallel imaging, which is most commonly employed for imaging most regions on modern MR systems.

When a person is placed inside the powerful magnetic field of the scanner, the magnetized protons (spins) align with the external magnetic field either along (spin up) or opposite (spin down) the direction of the magnetic field, a phenomenon referred to as the Zeeman effect. The spin-down position has higher energy than the spin-up. The principle of MRI depends on this small difference between the spins, which is influenced by the main magnetic field strength and estimated to be around 3 spins/million protons at 1 T.

When applying a 90° RF pulse, the net magnetization vector will produce longitudinal and transverse components. The time it takes the longitudinal magnetization to go exponentially from 0% to 63% of full magnetization (equilibrium value) is referred to as T1 relaxation time or spin-lattice relaxation. When the RF pulse is switched off, the longitudinal magnetization will return exponentially to zero in a time equal to T1. Different tissues have different T1 relaxation times (long for fluids, with the result that they appear dark on T1-weighted images, and short for fat, with the result that they appear bright on these images). Gadolinium-based contrast agents (GBCAs) cause T1 shortening, which renders tissues brighter.

When the RF pulse is switched off, the transverse magnetization will exponentially decay; when it reaches 37% of its original value, the time duration is referred to as T2 relaxation time or spin-spin relaxation. Different tissues have different T2 relaxation times (long for fluids, bright on T2-weighted images, and short for solid tissues, darker on T2-weighted images). Tissue T2 values, unlike T1 values, are not affected significantly by magnetic field strength.

The acquisition of the image requires the execution of a preselected predefined set of RF and gradient pulses at certain time intervals, known as pulse sequences, to generate an MR image of certain characteristics. These pulse sequences are computer commands that control all hardware aspects of the MRI measurement process.

The time required between each pulse is termed the time to repeat (TR). The time between the start of a pulse sequence and maximum signal is termed the echo time (TE). The time between a 180° inversion pulse and 90° excitation pulse in inversion recovery pulse sequences is termed inversion time (TI). TR and TE are always

employed in MR sequences (and TI, if utilized), are used to describe basic MR pulse sequences, and are all measured in milliseconds.

A combination of TR and TE is used to generate different image weighting. Short TR and TE provide T1 weighting, long TR and TE provide T2 weighting, and long TR and short TE provide proton density (PD) weighting.

The basic pulse sequences include conventional spin echo, fast spin echo, gradient-recalled echo, and inversion recovery sequences. More advanced MRI sequences include MRA sequences, echo-planar imaging/diffusion-weighted imaging sequences, magnetization transfer sequences, MR spectroscopy, and functional imaging.

Fat suppression applied to some acquisitions is an integral part of nearly all routine MR examinations, and this function is employed for tissue characterization and for emphasizing contrast agent enhancement. There are many fat-suppression techniques used in routine MRI, each with its own advantages and disadvantages. These include Dixon techniques, spectral fat saturation, water excitation, and fat suppression with inversion recovery (SPAIR and STIR).

The principle of parallel imaging is that different coils detect the signal from the same body part with different signal strengths due to their locations in space by applying the sensitivity maps of individual elements. Acceleration factor is a term used to denote the speed improvement achieved by combining the signal reception from imaging coils, where an acceleration factor of 2 represents a decrease in time of study of approximately 50%. Parallel imaging leads to significant reduction of scan time at acceleration factors of 2–3 while still achieving acceptable image quality with good signal-to-noise ratio (SNR) and minimal artifacts.

Image descriptors

MR images can be acquired in different planes: axial, coronal, and sagittal. Additionally, oblique planes can be planned based on these basic planes including long-axis and short-axis images. Similar to CT, three-dimensional (3D) MR data sets can be postprocessed on dedicated workstation to reformat the images in different planes termed MPR, MIP, and VR images.

Axial MR images are also interpreted as if the patient is being viewed from below, and coronal images are interpreted as if standing in front of the patient, where the left side of the image corresponds to the right side of the patient, and vice versa.

The appearance of structures on MR is described based on their intensities: hypo-, iso-, or hyperintense on T1- or T2-weighted images and hypo-, iso-, or hyperenhancing on postcontrast images, based on their level of enhancement compared to the background tissues/organs.

T1-weighted images can be recognized by the signal of different normal body tissues. Fluids show low T1 signal and high T2 signal intensities. Fat shows high T1 and intermediately high T2 signal intensities and suppresses on fat-suppression sequences, but not on opposed-phase T1-weighted images. Opposed-phase T1-weighted images can be used to detect intracellular, microscopic, intravoxel fat. Other common substances that can give high T1 signal (T1 relaxation time shortening) include gadolinium, protein, and methemoglobin.

Gray matter demonstrates lower T1 and higher T2 signal intensities compared to white matter. CSF demonstrates low signal on T1- and FLAIR-weighted images and high signal on T2-weighted images. T2 gradient-weighted images are very sensitive to susceptibility and are used to detect subtle blood degradation products and superparamagnetic substances, that is, iron.

Image performance

Contrast resolution

Contrast resolution depends on variations between the different tissues and is dependent on T1 and T2 times of these tissues. Flow also affects image contrast, and this property can be utilized in noncontrast-enhanced MR angiography. Gadolinium can also alter tissue contrast through T1 time shortening. PD imaging shows little intrinsic contrast because of the small variations in PD for most tissues.

Spatial resolution

Spatial resolution describes how sharp the image looks and is a product of pixel size. Pixel size equals the field of view divided by the data acquisition matrix size. In routine imaging, the spatial resolution is half that of CT. Higher-resolution imaging can be achieved in MRI, but at the expense of SNR.

SNR

SNR is the critical determinant for MR image quality. General factors like higher magnetic field and use of small-diameter surface coils (which are often aligned into a matrix of multiple coils, termed phased array) increase the SNR. SNR is also increased by increasing the slice thickness and/or decreasing the matrix size. Increasing the number of excitations, signal averages, or acquisitions increases the SNR but at the expense of increased scanning time.

Artifacts

Imaging artifacts in MRI can be divided into equipment-related or patient-related artifacts. One of the most important artifacts in MRI is motion related.

Motion appears as ghosting and blurring of the image along the phase-encoding direction, which is one of the directions of data acquisition in the XY plane (the other is frequency encoding). Motion artifacts can be the result of gross patient movement (nonperiodic) or secondary to respiratory or cardiac motion (periodic) motion. Nonperiodic movement is the most problematic, and it causes smearing across the image, and these types of artifacts may render studies uninterpretable. Periodic movement causes coherent ghosting, which are generally not so challenging.

Other artifacts include zipper, susceptibility, chemical shift, aliasing (wraparound), standing-wave, magic angel, cross-talk, and truncation artifacts.

Nuclear medicine

Nuclear medicine is a medical specialty that involves the application of radioactive material to either diagnose or treat diseases. Nuclear medicine primarily reflects physiological information, which on occasion can precede anatomical changes that are seen by other modalities.

Image production

Very heavy nuclei tend to be unstable. Unstable nuclides are called radionuclides. The transformation of a parent unstable nuclide into daughter nuclides is called radioactive decay. During that transformation, the mass number, electric charge, and total energy are unchanged.

Gamma rays (photons) are form of high-energy electromagnetic radiation that is emitted during radioactive decay and occasionally accompany the emission of alpha or beta particles. They have no mass or charge and interact less intensively with matter compared to ionizing particles. Gamma rays are comparable to X-rays both

in their imaging capabilities, and also in their potential to cause biologic radiation damage.

Image acquisition usually takes several minutes for full acquisition. Images can be viewed in real time on a display monitor during the acquisition, to monitor for gross motion, in addition to viewing the static images after the completion of a study data acquisition. Analog-to-digital converters (ADCs) are used to generate the digital information.

Nuclear medicine can be used for diagnostic (gamma rays) and interventional (beta particles) applications. Beta particles have higher energy but shorter traveling distances compared to gamma rays.

Most noncardiac applications in nuclear medicine utilize planar imaging. The exception is single-photon emission computed tomography (SPECT) imaging that provides computed tomographic views of the 3D distribution of radioisotopes in the body. SPECT imaging can be combined with CT (SPECT/CT). Low-dose CT scans are used for coregistration and attenuation correction only. Higher-dose CT scans can be acquired for diagnostic imaging.

In PET imaging, a ring of detectors (scintillators) surrounding the patient is used coupled with photomultiplier tubes to detect light produced in each detector. The detectors are thicker to allow the registration of incidence gamma photons. The positron travels for a distance of 0.4 mm and then collides with an adjacent electron, resulting in annihilation and emission of two 511 keV gamma ray photons at nearly opposite directions (coinciding photons). The simultaneous detection of coinciding photons allows for the identification of line of response and creation of a sinogram, which may be reconstructed using iterative reconstruction algorithms. The most commonly used agent in PET imaging is fluorine-18 fluorodeoxyglucose (18F-FDG), which has a half-life of 110 min. 18F undergoes beta minus decay with the emission of a positron.

PET/CT uses a hybrid of PET and CT imaging. The principle is similar to SPECT/CT. Most recently, systems have been developed in which PET can be simultaneously acquired in combination with MRI (MR/PET).

Image descriptors

Nuclear medicine images are divided into planar, SPECT, or PET images. Most applications require the acquisition of whole-body images from two cameras while the patient is lying supine on the imaging table, which results in two images (anterior and posterior projections).

Planar images are usually displayed in pairs with two different windows and sent to PACS or printed on films. Additionally, spot images can be acquired as part of routine imaging or as a problem-solving addition. Spot images can have different projections. On the anterior projection images, the left side of the image corresponds anatomically to the right side of the patient. On the posterior projection images, the left side of the image corresponds anatomically to the left side of the patient.

SPECT and PET images are obtained in axial plane and can be reconstructed into coronal and sagittal plane images. SPECT and PET images are displayed in the same fashion as CT and MRI where the left side of the image corresponds to the right side of the patient.

Terms used to describe imaging findings in nuclear medicine are different from those used to describe other radiologic studies. Areas of increased activity are described as areas of increased uptake. Areas with decreased activity are referred to as areas of decreased uptake. Areas with no activity are often referred to as photopenic areas.

Image performance

Spatial resolution in nuclear medicine is the ability to distinguish two adjacent radioactive sources. The most common method to measure resolution is to measure the full width half maximum of the imaged line source of activity. It depends on the width of the camera and the collimators. SPECT has the lowest spatial resolution.

Image contrast is the difference in intensity (counts) between a specific tissue or organ and background and depends on the concentration of the radiopharmaceutical in the targeted tissue (target-to-background ratio). The background count is proportional to collimator septal penetration and scatter.

Noise, also called quantum mottle, is much higher in nuclear medicine compared to X-ray imaging because the number of photons used to generate an image is low. SPECT imaging has the highest noise due to the low number of photons used to reconstruct each voxel.

Artifacts

Motion artifact, as in all radiological modalities, is the most common artifact in nuclear medicine. The most problematic, as with other modalities, is gross patient motion.

Image defects can be of different appearances. The appearance of the defect can be characteristic for malfunction of a specific component within the imaging system. Common defects related to external effects include metallic implants or dense contrast material (e.g., barium).

Contrast agents

A radiological contrast agent (or contrast media) is a substance used to emphasize the appearance of structures within the body and is commonly used to enhance the visibility of blood vessels, GI tract, or disease process.

Radiographic contrast agents

Radiographic contrast agents may be used with all imaging techniques to enhance the differences between body tissues. Ideally, contrast agents should achieve a high concentration in the body without producing any adverse effects. Unfortunately, this target has not yet been achieved, and all contrast agents have potential adverse effects.

They are classified into positive and negative agents. Positive contrast agents can be divided into water and nonwater soluble. Air is often referred to as a negative contrast agent, which can be used alone or in addition to other positive contrasts to achieve a double contrast effect.

Non water-soluble agents consist of a suspension of insoluble barium. These agents are only used for GI tract imaging and are not absorbed.

Iodine-based contrast agents are water soluble and are based on a molecular structure of three-iodine atom attached to a benzene ring (tri-iodinated benzene ring). Based on the number of tri-iodinated benzene rings, these agents are classified into monomers and dimers.

Iodine-based contrast agents can be classified into ionic and nonionic based on their electrical structure. They can be further classified based on their osmolality into hypo-, iso-, and hyperosmolar agents. They can be given intravenously or orally or injected into different abdominopelvic cavities.

Iodine-based contrast agents have different viscosities, which is a function of solution concentration, molecular structure, and interactions with water molecules.

Iodine-based contrast agents are distributed throughout the extracellular space when administered intravenously. They enhance the diagnostic performance of CT and conventional diagnostic angiographic procedures. They can also be administered directly into the body cavities, for example, the GI tract and the urinary tract.

Ultrasonographic contrast agents

Contrast agent can also be used to enhance the diagnostic value of US. These agents are composed of microbubbles that persist in the bloodstream for several minutes, which in combination with specialized US techniques (harmonics) allow a definite improvement in the contrast resolution and suppression of signal from stationary tissues.

These agents are commonly used to enhance the conspicuity of solid organ lesions, either for diagnostic or interventional purposes, and to offer enhancement characterization of these lesions. They can also be used to augment the diagnostic value of Doppler US to assess solid organ perfusion, especially following transplantation.

MR contrast agents

Contrast agents in MRI are divided into positive (paramagnetic) and negative (superparamagnetic) contrasts.

Negative agents are iron based and cause significant T2/T2* shortening; these agents can cause significant T1 shortening during their vascular phase, but once internalized within the reticuloendothelial system, they have negligible effect on T1 relaxation time. Currently, none of these agents are commercially available, apart from an oral preparation.

Positive agents are gadolinium based (the great majority), and they cause T1 and T2 shortening, with the most prominent effect, which is employed in most clinical applications, being the T1-shortening effect. T1 enhancement is best shown on T1-weighted images, with the appearance of tissue brightening. Gadolinium is a heavy metal and is very toxic in its free form. In Gadolinium-based contrast agents (GBCAs), the gadolinium ion is bound to ligand forming a chelate to minimize toxicity.

There are a variety of ways to classify GBCAs based on various properties that they possess. One common classification is based on the molecular structure of the agent, where more stable (hence often “safer”) structures are macrocyclic and less stable structures are linear and as an independent property ionic (more stable) and nonionic (less stable). GBCAs can also be classified into extracellular agents or mixed extracellular/organ-specific (hepatocyte) agents.

Extracellular GBCAs do not show appreciable binding to protein and are solely excreted by the kidneys, while agents with protein-binding property are excreted to a varying extent through the bile as well as the kidneys.

The following GBCAs in clinical usage are described with their structure: gadoterate meglumine (Dotarem) is an ionic macrocyclic agent, gadoteridol (ProHance) and gadobutrol (Gadavist) are non-ionic macrocyclic agents, and gadopentetate dimeglumine (Magnevist) and gadobenate dimeglumine (MultiHance) are ionic linear agents.

Ionic linear GBCAs with dual elimination are gadobenate dimeglumine (MultiHance) and gadoxetate disodium (Eovist/Primovist), which also exhibit high relaxivity (greater tissue brightening).

Different GBCAs have different r1 and r2 relaxivities, also termed T1 and T2 relaxivity. Protein binding often results in heightened relaxivity, with the net effect that enhancement is more intense on T1-weighted images.

Immediately after IV injection, extracellular and protein-bound agents behave the same and exhibit the same extracellular distribution

and excretion as iodine-based agents. However, protein-binding agents are taken up by hepatocytes and excreted into the bile in addition to their renal excretion. Protein binding also allows for longer intravascular dwell time in some of these agents.

Nuclear medicine radiopharmaceuticals

Radionuclides are combined with existing pharmaceutical compounds to form radiopharmaceuticals. They are designed to mimic a natural physiologic process and localize in the organ or tissue of interest by different mechanisms including compartmentalization, active transport, simple exchange, phagocytosis, or capillary blockage.

Technetium (^{99m}Tc) is a radiotracer used in approximately 80% of all nuclear medicine examinations. It is considered an ideal radiotracer because it has gamma ray energy of 140keV and a convenient t half-life of 6 h. Pertechnetate ($^{99m}\text{TcO}_4^-$) is produced directly from a shielded generator containing ^{99}Mo using a saline eluant. A ^{99m}Tc generator is normally eluted daily over the course of a week and then replaced.

There are many radiopharmaceuticals used for different clinical applications with different chemical properties.

Biological effects

Ionizing radiation modalities

Ionizing radiation results in ejection of an electron from a neutral atom, which becomes positively charged. X-rays, gamma rays, and ultraviolet radiation are all considered ionizing radiations. Table 1.1 demonstrates the effective dose of common radiological examinations.

X-ray-based modalities

Although large doses of ionizing radiation are known to cause cancer, there has been controversy whether lower doses, in the range observed with CT scans (5–50mSv), pose a risk.

Sponsored by several federal agencies, the seventh Biological Effects of Ionizing Radiation (BEIR) report [1] updated the health risks from low linear energy transfer radiation (≤ 100 mSv), which deposits little energy in a cell and thus tends to cause little damage. It was stated that there is no threshold below which there is no risk, and that as exposure increases, so does the health risk (linear-no-threshold model).

Table 1.1 Radiation dose estimates for common radiological techniques in mSv.

Diagnostic examination	Effective dose (mSv) ^{1,2}
Chest X-ray (PA film)	0.02
Lumbar spine X-ray	1.8
Extremity X-ray	0.001
Mammogram (two views)	0.36
CT head	2
CT coronary angiography	5–32
Cardiac CT for calcium scoring	3
CT chest	10
CT abdomen	10
18F-FDG PET/CT	25
Cardiac 201Tl chloride	41
Coronary angiography (therapeutic)	15
Transjugular intrahepatic portosystemic shunt (TIPS) placement	70

¹The effective doses are typical values for an average-sized adult. The actual dose can vary substantially, depending on a person's size as well as on differences in imaging practices.

²The use of effective dose for assessing the exposure of patients has severe limitations that must be considered when quantifying medical exposure.

The linear-no-threshold model predicts that any dose, no matter how small, may produce health effects based on the hypothesis that a single ionizing event can result in DNA damage. From a practical standpoint, low-dose procedures such as chest X-rays (0.10 mSv) are treated differently from high-dose procedures such as CT (2–20 mSv), as risk related to individual low-dose procedures is likely largely nonexistent.

Much of the data for radiation risk has been derived from atomic bomb survivors from Japan, and until relatively recently, reliable data on the risks related to CT imaging have been lacking.

In 2012, two important studies were published describing more direct evidence of risk of malignancy development. Pearce et al. [2] reported a study on pediatric patients who underwent CT examination in Great Britain. They showed that the use of CT scans in children that delivered cumulative doses in the range of 50 mGy might almost triple the risk of leukemia and doses of about 60 mGy might triple the risk of brain cancer. Mathews et al. [3] reported on 680,000 Australians who underwent a CT scan when aged 0–19 years and showed that malignancy incidence was increased by 24% (95% CI: 0.20–0.29) compared with the incidence in over 10 million unexposed people. Their study also showed that the proportional increase in risk was evident at short intervals after exposure and was greater for persons exposed at younger ages. They reported that absolute excess cancer incidence rate was 9.38 per 100,000 person-years at risk and that the incidence rates were increased for most individual types of solid cancer and for leukemias, myelodysplasias, and some other lymphoid tumors.

A third large-scale study, reported by Eisenberg et al. [4] involving 82,861 patients who had an acute myocardial infarction and no history of cancer, described 64,000 patients who underwent at least one cardiac imaging or therapeutic procedure in the first year after acute myocardial infarction. They reported that for every 10 mSv of low-dose ionizing radiation, there was a 3% increase in the risk of age- and sex-adjusted cancer over a mean follow-up period of 5 years.

Nuclear medicine

Radiation exposure is extremely high with a number of nuclear medicine studies, notably thallium studies and CT/PET. CT/PET is reported to have an exposure of 25 mSv, but much of that radiation is attributable to the CT part of the study, and approximately 5 mSv from PET.

Nonionizing radiation modalities

US and MRI

Present data have not conclusively documented any deleterious effects of cancer induction or fetal defects secondary to either US or MRI.

Contrast-related adverse events

Contrast reactions are classified into acute, subacute, and chronic reactions based on the interval between contrast administration and development of side effects.

Acute adverse reactions are defined as reactions occurring within an hour up to 48 h following contrast medium injection. There is increased risk for developing acute adverse events in patients with history of asthma or history of allergy to other contrast agents.

Allergic acute reactions have been classified as mild, moderate, or severe. Mild reactions usually do not need treatment and include nausea, vomiting, urticaria, and itching. Moderate reactions include severe vomiting, marked urticaria, bronchospasm, facial or laryngeal edema, and vasovagal reactions. Severe reactions include hypotensive shock, pulmonary edema, cardiopulmonary arrest, and convulsion.

The management of acute adverse reactions is identical whether they are caused by iodine- or gadolinium-based agents or by US agents. Nausea, vomiting, hives, and pruritus are usually self-limited. However, patients should be observed closely for systemic symptoms while IV access is maintained. If the urticaria is extensive or bothersome to the patient, antihistamines, such as Benadryl, may be given.

Bronchospasm without coexisting cardiovascular problems should be treated with high rate oxygen (6–10 L/min) and inhaled beta-2 agonist bronchodilators (two to three deep inhalations).

Isolated hypotension is best managed initially by rapid IV fluid replacement rather than vasopressor drugs. Large volumes may be required to reverse the hypotension. Vagal reactions are characterized by the combination of prominent sinus bradycardia and hypotension. Treatment includes patient leg elevation and rapid infusion of IV fluids. The bradycardia is treated by IV administration of atropine to block vagal stimulation of the cardiac conduction system.

Anaphylactoid reactions are acute, rapidly progressing, systemic reactions characterized by multisystem involvement. Initial treatment includes maintenance of the airway, administration of oxygen, rapid infusion of IV fluids, intramuscular adrenaline (0.3–0.5 mL of 1:1000), electrocardiogram (ECG) monitoring, and slow administration of adrenaline.

Iodine-based contrast agents

Acute adverse events

Acute adverse reactions (as described in the section “Contrast-related adverse events”) to iodine-based contrast media are almost always associated with intravascular administration. Prompt recognition and treatment are essential.

Contrast medium-induced nephropathy

Contrast medium-induced nephropathy (CIN) is defined as an onset of diminished renal function that occurs shortly after contrast agent administration without other predisposing causes. Current practice for preventing CIN still relies on identifying patients at increased risk.

Preexisting renal impairment, defined as an effective glomerular filtration rate (eGFR) of less than 60, is the most important risk factor for CIN. CIN has been seen with all stages of chronic renal disease, but most often with stages 3–5. CIN has been reported in patients with normal renal function in 0.6–2.3%, but this is most often a transient effect on renal function.

The risk of developing CIN in patients with renal impairment is about 3–21% when contrast is administered intravenously and 3–50% when given intra-arterially. The risk of CIN is greater if renal impairment is associated with diabetes mellitus, hypertension, and concurrent use of metformin or nephrotoxic medications. The risk of requiring dialysis in patients developing CIN is 3%, with a 1-year mortality rate of 45% for these patients.

A number of measures have been proposed to reduce the incidence of CIN, but the most important, and consistently observed as beneficial, patient preparation is to ensure good hydration, which may require IV administration of fluid.

Dialysis is effective for eliminating iodine-based contrast media.

Contrast extravasation

Extravasation of contrast medium during injection is a common problem. The mechanism of injury is related to chemical and tissue compression effects. The clinical picture varies from trivial pain

and redness at the site of injection to (rarely) skin ulceration and compartment syndrome.

When extravasation is identified, the injection should be immediately terminated. The injection site should be carefully inspected. The patient should be advised to elevate the involved limb. Alternating hot (to induce vasodilatation and promote absorption of the extravasated material) and cold (to induce vasoconstriction and limit inflammation) compresses, performed a few times per day for the first few days, is recommended.

Gadolinium-based contrast agents (GBCAs)

Acute adverse events

Acute adverse reactions may occur after administration of GBCAs; however, their rate is much lower compared to iodine-based agents. There may be no difference in the rate of acute adverse events between the different GBCAs. Acute adverse event and their medical management are similar to those of iodine-based contrast agents.

Nephrogenic systemic fibrosis

Nephrogenic systemic fibrosis (NSF) is an important subacute adverse reaction to nonchelated gadolinium, with onset typically occurring between 2 months and 2 years after GBCA administration.

Patients who are at high risk to develop NSF are those with stage 4–5 chronic kidney disease (CKD), in particular stage 5, and those with severe acute renal failure. The type of GBCA used also plays an extremely important role in NSF, with linear nonionic agents having the highest causal association.

Agents with low risk include MultiHance, Eovist/Primovist, and Ablavar/Vasovist (which are ionic linear agents that possess additional hepatobiliary elimination), and ProHance, Dotarem, and Gadavist (which are macrocyclic agents).

In efforts to avoid causing NSF, guidelines for the utilization of GBCAs have been developed and generally employed at all institutions. The bases of these guidelines include avoiding the use of nonionic linear agents in patients with renal impairment and avoiding repeated doses of GBCAs in patients with poor renal function. Routine determination of eGFR is generally advised in patients at risk of having poor renal function.

Summary

Remarkable advances in radiology have been achieved in the last three decades. In addition to the strengths, it is imperative to understand associated risks and biological effects. It is the responsibility of the radiologist and requesting physician to consider the risk and benefit of each radiological investigation and to choose the appropriate, yet sufficiently safe, technique based on the available data of probabilistic risk assessments (Table 1.2).

Table 1.2 Probabilistic risk estimates of contrast agents' adverse effects.

Event	Incidence
CIN in patients with renal impairment	1 in 5
NSF from Omniscan in patients with renal impairment	1 in 25
CIN in patients with normal renal function	1 in 50
Cancer from 10 mSv of radiation (1 body CT)	1 in 1,000
NSF from Omniscan	1 in 2,500
NSF from Magnevist	1 in 40,000
Death from anaphylactoid reaction to nonionic iodine-based contrast	1 in 130,000
Death from anaphylactoid reaction to gadolinium-based agents	1 in 280,000
NSF from MultiHance, ProHance, Gadavist, and Dotarem	<1 in 10,000,000 for each

The use of nonionizing radiation modalities should always be considered, especially in more radiosensitive populations. Physicians should also avoid requesting redundant examinations and unnecessary short-term follow-ups. Specific considerations have been provided in this chapter that allow the understanding of basic imaging principles and safety practices.

Reference

- 1 National Research Council (US) Committee on the Biological Effects of Ionizing Radiation (BEIR V). *Health Effects of Exposure to Low Levels of Ionizing Radiation: BEIR V*. Washington, DC: National Academies Press (US), 1990. Available at <http://www.ncbi.nlm.nih.gov/pubmed/25032334>. Accessed October 31, 2014.
- 2 Pearce, M. S., Salotti, J. A., Little, M. P., McHugh, K., Lee, C., Kim, K. P., et al. (2012) Radiation exposure from CT scans in childhood and subsequent risk of leukaemia and brain tumours: a retrospective cohort study. *Lancet*, 380(9840), 499–505. doi:10.1016/S0140-6736(12)60815-0
- 3 Mathews, J. D., Forsythe, A. V., Brady, Z., Butler, M. W., Goergen, S. K., Byrnes, G. B., et al. (2013) Cancer risk in 680,000 people exposed to computed tomography scans in childhood or adolescence: data linkage study of 11 million Australians. *BMJ (Clinical Research Ed.)*, 346, f2360.
- 4 Eisenberg, M. J., Afilalo, J., Lawler, P. R., Abrahamowicz, M., Richard, H., & Pilote, L. (2011) Cancer risk related to low-dose ionizing radiation from cardiac imaging in patients after acute myocardial infarction. *CMAJ : Canadian Medical Association Journal = Journal De l'Association Medicale Canadienne*, 183(4), 430–436. doi:10.1503/cmaj.100463

Suggested reading

- ACR Committee on Drugs and Contrast Media ACR Manual on Contrast Media (V9). ACR Manual on Contrast Media (9 ed.), 2013. Retrieved from <http://www.acr.org/quality-safety/resources/contrast-manual>. Accessed October 31, 2014.
- Amis, E.S., Jr & Butler, P.F. (2010) ACR white paper on radiation dose in medicine: three years later. *Journal of the American College of Radiology*, 7 (11), 865–70.
- Allisy-Roberts, P.J. & Williams, J. (2008) *Farr's Physics for Medical Imaging*. Saunders, Edinburgh, New York.
- Huda, W. (2010) *Review of Radiologic Physics*. Lippincott Williams & Wilkins, Baltimore, MD.
- Westbrook, C., Kaut Roth, C. & Talbot, J. (1998) *MRI in Practice*. Blackwell Science, Malden, MA.

CHAPTER 2

Imaging studies: What study and when to order?

Kiran Reddy Busireddy, Miguel Ramalho, and Mamdoh AIObaidy

Department of Radiology, University of North Carolina, Chapel Hill, USA

Radiology at present is the key diagnostic tool for numerous disease processes and has also an important role in monitoring treatment and predicting outcome. It is well recognized that imaging achieves a great proportion of diagnosis in daily clinical practice and changed the way how medicine is performed. The improved image resolution and tissue differentiation in a number of conditions dramatically augment the range of diagnostic information and in many cases the demonstration of pathology without the requirement of invasive tissue sampling. New knowledge in imaging is being developed at an increasingly rapid rate, and the field of radiology has expanded dramatically.

There are a number of imaging modalities with differing physical principles of varying complexity. Despite the recent technological advances, different imaging investigations have strengths and weaknesses, and development of appropriate integrated imaging algorithms to maximize clinical effectiveness is recommended. The referring physicians need a clinical interface with the imaging specialist, ensuring the best use of assets and health-care resources.

The imaging tests that the health-care team recommends depend on a number of factors, such as what type and where the pathology is, as some imaging studies work better for certain organs or tissues; whether or not a biopsy (tissue sample) is needed; the balance between any risks or side effects and the expected benefits; and overall cost.

In this chapter, we describe the role of specific imaging methods for different organ systems and recommend the modalities for common disease processes, maximizing the use of resources. Also, we have included imaging workup algorithms for the few most commonly found clinical scenarios. These are very similar to the American College of Radiology (ACR) appropriateness criteria, which is recognized as the best compendium of recommendations of imaging exams and can be found at <http://www.acr.org/quality-safety/appropriateness-criteria>. Overall, the recommendations listed here provide additional weighting to magnetic resonance imaging (MRI) for many indications, reflecting heightened

MR image quality of new MR systems and the intrinsic safety of MRI.

Respiratory system

Plain radiography (PXR) and computed tomography (CT) are the predominant imaging modalities used to evaluate the respiratory system.

Plain radiography is often used as a first imaging modality to evaluate signs and symptoms related to the respiratory, cardiac, and bony structures of the thorax.

CT is used for further evaluation when PXR is normal or equivocal and when there is a high suspicion of a clinically significant disease. Other indications of PXR are preoperative evaluation and follow-up of known thoracic disease processes to assess for improvement, progression, or resolution.

High-resolution computed tomography (HRCT) is the examination of choice to evaluate suspected small and large airway diseases, to demonstrate and differentiate the diffuse pulmonary diseases (especially interstitial lung disease), to assess the extent of diffuse disease pathology, and to determine the best site for biopsy.

MRI has a limited role in evaluating respiratory diseases because of the low proton density of normal lung, the decrease of signal by susceptibility artifacts induced by the air-soft tissue interfaces within the lung, and the consequences of cardiac and respiratory movement. One possible indication of chest MRI is suspicion of pulmonary embolism (PE) if radiation and intravenous (IV) iodinated contrast medium need to be avoided.

Ventilation/perfusion (V/Q) scintigraphy is a noninvasive technique for assessing the probability of acute or chronic pulmonary thromboembolic disease. Pulmonary scintigraphy is also indicated for evaluating the effect of congenital heart diseases or pulmonary arterial pathologies on pulmonary perfusion and regional lung function pre- and postoperatively, including post-lung transplant patients. Ionizing radiation is delivered with this modality in the form of gamma rays.

Imaging role and workup algorithms for selected clinical scenarios

Chest trauma

- PXR remains the initial diagnostic modality for all chest trauma patients.
- CT possesses high sensitivity and specificity and is often helpful in rapid assessment of emergency patients presenting with chest trauma.

Hemoptysis

Chronic bronchitis, pneumonia, bronchiectasis, malignancy, fungal infections, and tuberculosis are the most common causes of hemoptysis. Refer to the imaging workup algorithm for hemoptysis:

- CT imaging should be considered for further evaluation in patients who are active or ex-smokers with a chest radiograph showing no abnormalities.
- Patients with greater than 40 years of age or greater than 40 pack-year smoking history with a negative PXR, CT scan, and bronchoscopy should be followed with PXR or CT imaging for the next continuous 3 years as they are considered to be at high risk for lung cancer.

Acute respiratory illness

The presence of one or more of the following symptoms such as cough, sputum production, chest pain, or dyspnea with or without associated fever is known as acute respiratory illness (ARI). The choice of imaging study also depends on many factors, such as patient's age, clinical history, physical examination, the presence of other risk factors, severity of illness, and the presence of fever or increased white blood cell count or hypoxemia. Refer to the ARI imaging workup algorithm:

- In patients presenting with ARI, the workup usually involves PXR and CT.
- In patients presenting with chronic obstructive pulmonary disease (COPD) and asthma exacerbations, PXR is not indicated unless there is a suspected complication such as pneumonia or pneumothorax or in the presence of one or more of the following:

chest pain, leukocytosis, history of coronary artery disease, or congestive heart failure.

- PXR is also considered in adult patients with a clinical suspicion of pneumonia, although some clinicians may not choose to request any imaging if clinical suspicion of respiratory infection is sufficiently high to initiate treatment.
- PXR is indicated early in the evaluation of immunocompromised patients presenting with ARI, and further CT imaging is not warranted if a plain radiograph shows a single, focal airspace abnormality in a patient with acute bacterial pneumonia symptoms.
- CT without contrast is indicated in patients with nonresolving pneumonia or severe pneumonia with multilobar involvement or if any intervention is contemplated. Further imaging with CT may not be needed.

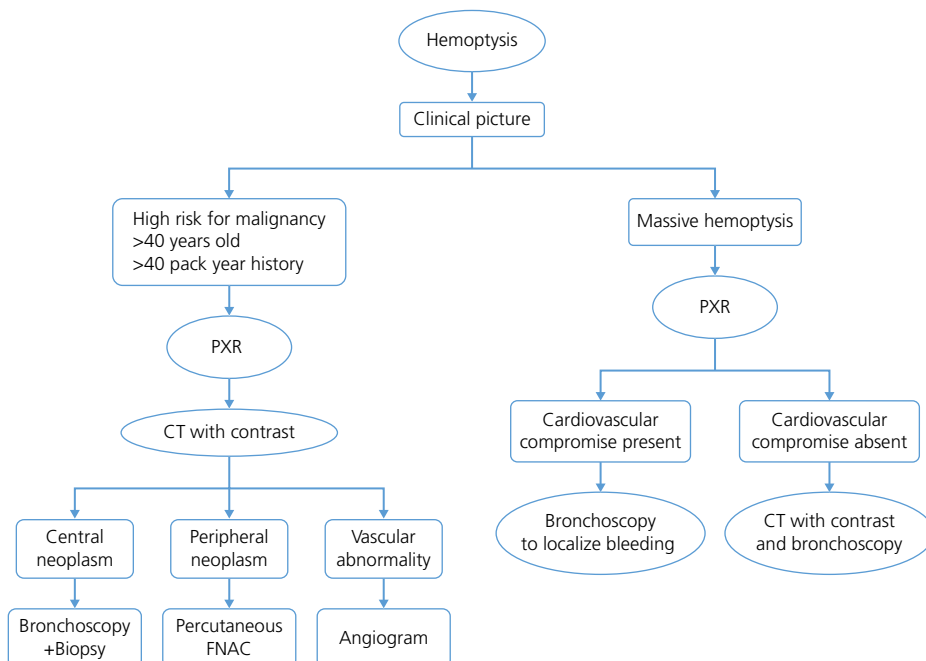
Dyspnea

Asthma, emphysema, PE, pneumothorax, upper airway obstruction, and interstitial lung disease are the most common causes of dyspnea. Dyspnea is classified into acute, lasting a few minutes to a few hours, or chronic, lasting greater than a month:

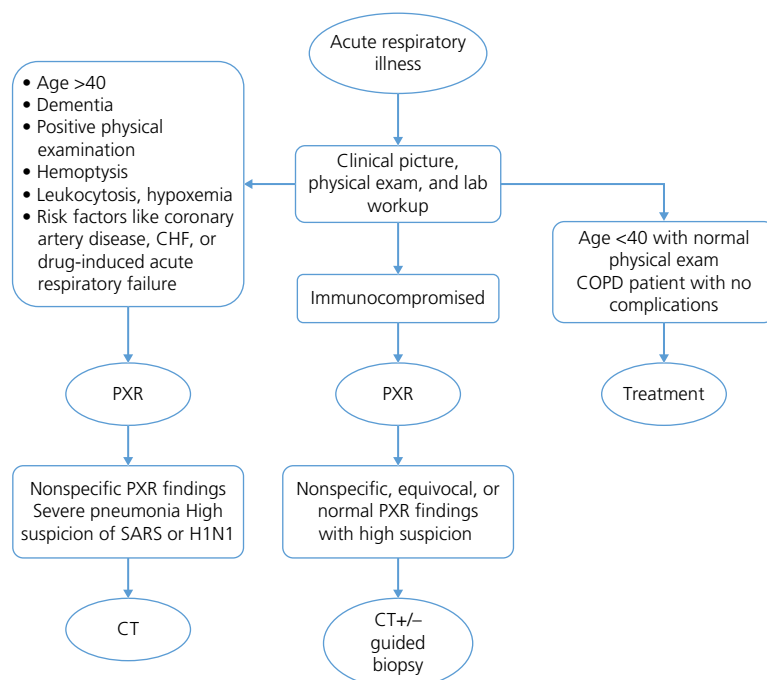
- In the setting of chronic dyspnea, a negative chest PXR does not rule out diffuse pulmonary disease and should be followed with HRCT imaging.
- HRCT is also indicated in a situation where PXR reveals an abnormality, but no definitive diagnosis can be made.
- Transesophageal echocardiography (TEE) and transthoracic echocardiography (TTE) are widely performed procedures that play a significant role in evaluating patients with dyspnea suspected from cardiac diseases.

Solitary pulmonary nodule

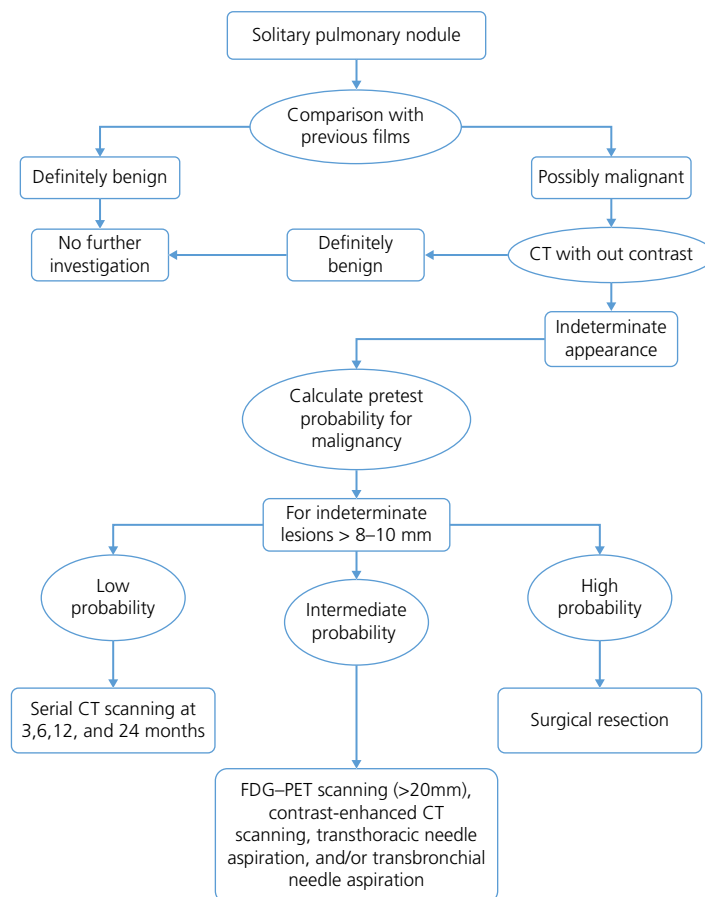
Solitary pulmonary nodule is defined as a rounded opacity less than or equal to 3 cm in diameter, surrounded by a normal lung parenchyma with no associated abnormalities such as atelectasis or hilar lymphadenopathy. These nodules are usually followed by CT. Refer to the solitary pulmonary nodule imaging workup algorithm.



PXR, plain X-ray; CT, computed tomography; FNAC, fine needle aspiration cytology.



PXR, pain X-ray; CT, computed tomography; CHF, congestive heart failure; COPD, chronic obstructive pulmonary disease; SARS, severe acute respiratory syndrome; +/- with or without.



CT, computed tomography; FDG-PET-fludeoxyglucose-positron emission tomography

Lung cancer

Histologic confirmation of the lung cancer is mandatory in all patients, unless there is a clear-cut evidence of multiple sites of metastatic disease:

- Lung cancer staging employs a number of imaging modalities such as PXR, CT, MRI, and fluoro-2-deoxy-D-glucose positron emission tomography (FDG PET). Small cell lung cancer staging involves imaging of CT chest and abdomen, FDG PET, and imaging of the central nervous system (CNS), preferably with MRI.
- Non-small cell lung cancer staging consists of chest CT and FDG PET, whereas CNS imaging with MRI is considered only in symptomatic and high-risk cases.

Cardiovascular system

PXR is indicated for evaluating signs and symptoms potentially related to the heart and is considered the initial modality for clinically suspected conditions such as heart enlargement, heart failure, and pulmonary edema and for monitoring treatment for these conditions.

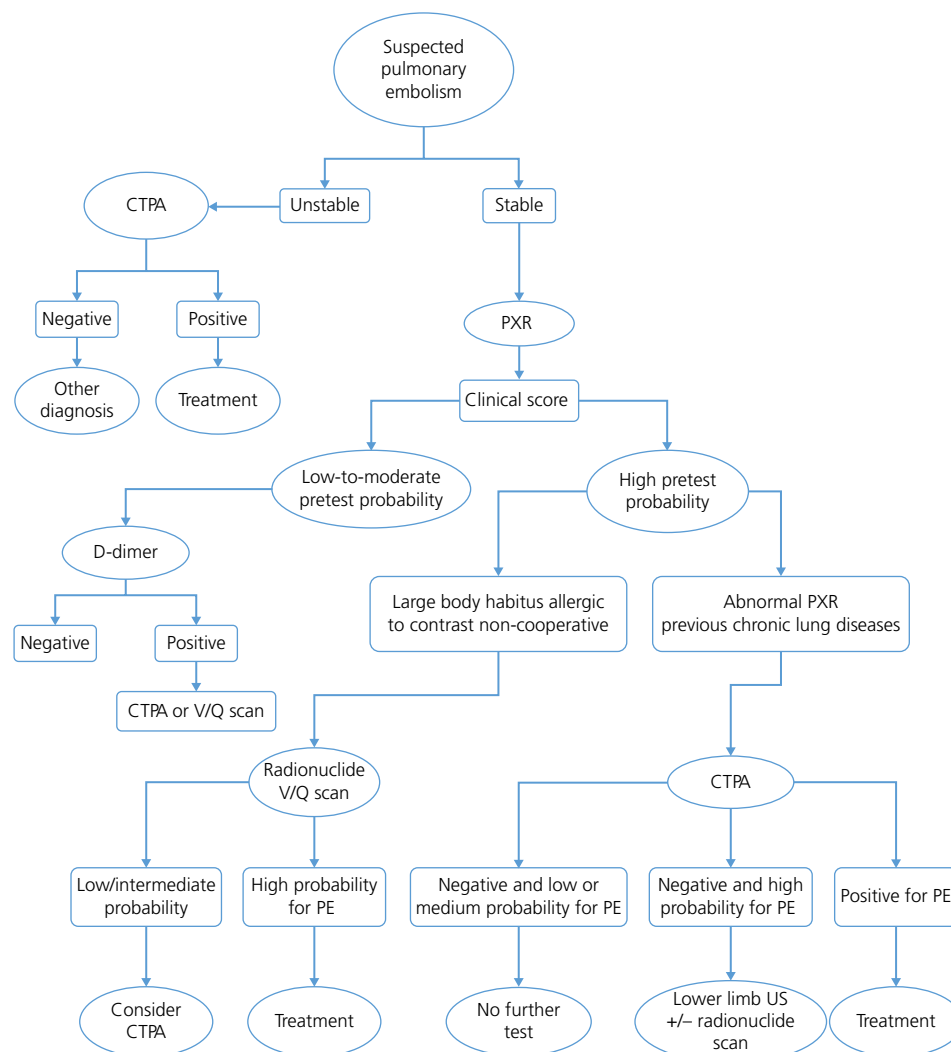
Cardiac CT in addition to evaluating the anatomy and pathology can also assess the central great vessels and cardiac valves including the cardiac function.

ECG-gated unenhanced cardiac CT may be indicated for detecting and quantifying coronary artery calcium, that is, calcium score, and for localizing myocardial, pericardial, valvular, and aortic calcium. Pericardial effusion, masses, the position of the implants, and postoperative complications such as focal fluid collections can be readily seen on an unenhanced cardiac CT. The use of IV contrast medium allows better evaluation of the cardiac chambers and adjacent vascular anatomy.

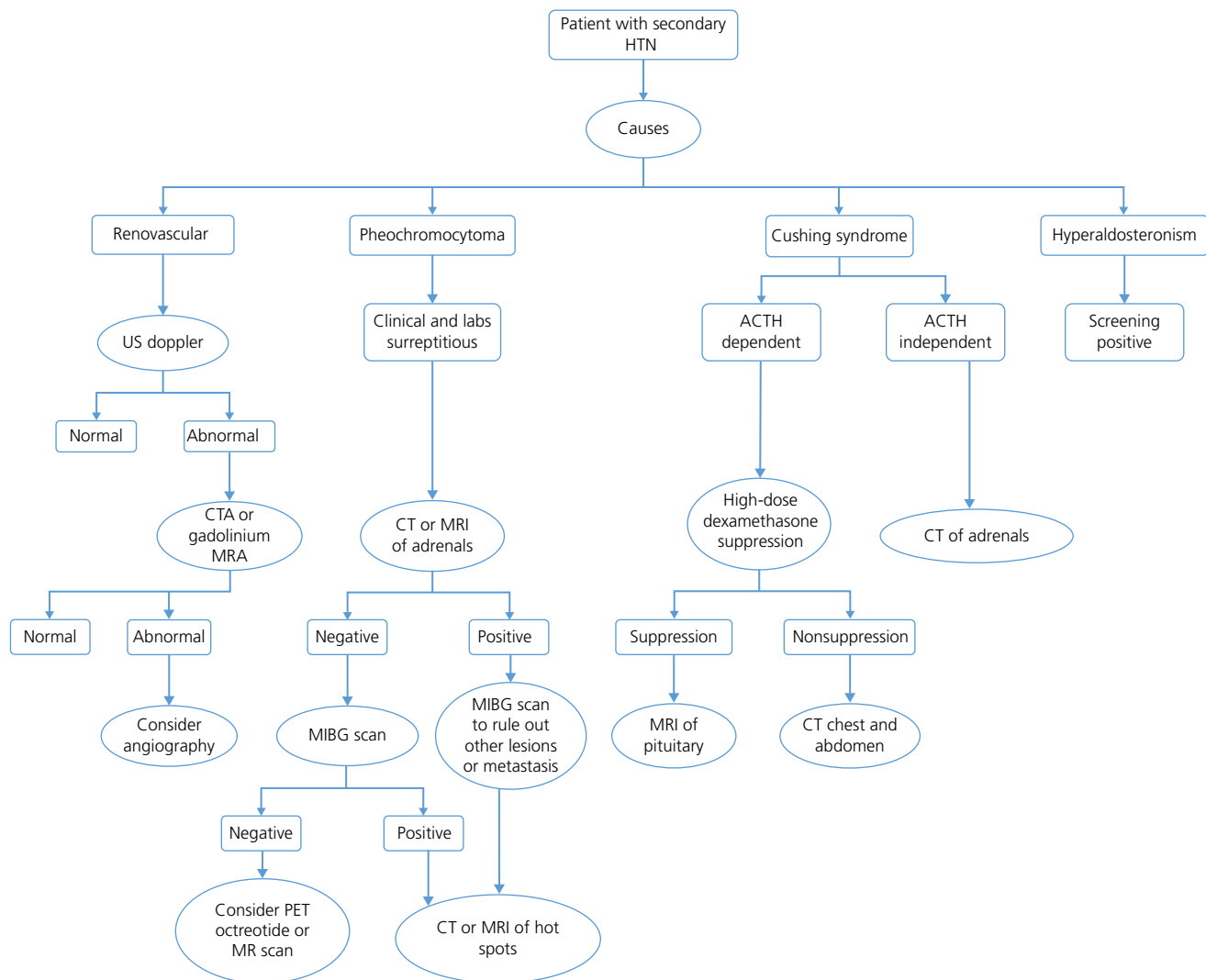
CT is used to screen for, diagnose, or characterize the great vessel pathology (atherosclerosis, arterial dissection, intramural hematoma, aneurysms, and vascular infection, vasculitis, and collagen vascular diseases), cardiac abnormalities, ventricular function, myocardial viability, myocardial perfusion, and coronary artery anatomy including narrowing and stenosis.

Cardiac magnetic resonance (C-MR) imaging is well known for its increasing value in the initial assessment and monitoring of a wide range of cardiac diseases, including cardiomyopathy, congenital heart disease, congestive heart failure, valvular heart disease, and cardiac tumors as well as the evaluation of the surrounding anatomy. However, in some patients with implantable devices, CT imaging is indicated as artifacts due to metal are less of a problem in CT compared with C-MR.

Contrast-enhanced magnetic resonance angiography (CE-MRA) is comparable to conventional angiography in the assessment of the



PXR, plain X-ray; CTPA, computed tomography pulmonary angiogram; V/Q scan, ventilation/perfusion scan; US, Ultrasonography.



US, Ultrasonography; CTA, computed tomography angiography; MRA, magnetic resonance angiography; CT, computed tomography; MRI, magnetic resonance imaging; ACTH, adrenocorticotropic hormone; MIBG, metaiodobenzylguanidine scan.

vascular system and the associated diseases and thus helpful for pretreatment planning. CE-MRA is increasingly used to evaluate myocardial perfusion and evaluation of infarcts.

The main goal of cardiac scintigraphy is to assess myocardial perfusion and/or function, to detect physiologic and anatomic abnormalities of the heart, and to determine the prognosis.

Imaging role and workup algorithms for selected clinical scenarios

PE

- CT angiography (CTA) of the chest is now the first-line approach in the assessment of suspected PE.
- V/Q scanning is indicated only if contrast-enhanced CT is contraindicated in the evaluation of suspected PE.
- MRA is an alternative method, which has an additional advantage of nonionizing radiation side effects.
- Patients evaluated for PE in the emergency department are frequently young and often present with other disease processes that may mimic symptoms of PE. There is an incidence of about 5% of PE in young patients. If available, MRA should be regarded as a first choice for the evaluation of young patients.

Refer to the imaging workup algorithm for pulmonary embolism.

Secondary hypertension

Hypertension with an underlying, potentially correctable or reversible cause is termed as secondary hypertension. A secondary etiology can be suggested by findings such as flushing and sweating suggestive of pheochromocytoma, a renal bruit suggestive of renal artery stenosis, or hypokalemia suggestive of aldosteronism. Secondary hypertension should also be considered in patients with hypertension resistant or refractory to treatment, in young patients, and in patients with a history of renal disease. Refer to the imaging workup algorithm for secondary hypertension.

Deep venous thrombosis

The initial screening workup for a suspected deep venous thrombosis (DVT) includes clinical risk score (i.e., Wells criteria) along with plasma D-dimer assessment. Both Wells scoring and D-dimer assessment, however, have limitations, and imaging is ultimately required for the confirmation of DVT and to plan for a proper treatment:

- Ultrasonography (US) is the most cost-effective imaging performed to diagnose DVT.
- In the setting of pelvic and thigh DVT, MRI and CT are the choice of imaging to evaluate pelvic and thigh DVT if US is nondiagnostic.

Gastrointestinal system

Plain abdominal radiographs are still commonly performed for the initial assessment of the clinically acute abdomen, which include evaluation for suspected bowel perforation in unstable patients, bony fractures in blunt trauma, pneumoperitoneum, possible toxic megacolon, and follow-up of bowel obstruction, nonobstructive ileus, and abdominal distension.

Modified barium swallow is a procedure performed for evaluation of the oral and pharyngeal phases of swallowing and is used mainly for evaluation of oropharyngeal dysphagia and disorders affecting swallowing (e.g., neurological, myopathy conditions, masses) and for oral feeding assessment in stroke, trauma, and ventilator-dependent patients.

Single-contrast and double-contrast upper gastrointestinal (GI) series are procedures performed for evaluating signs and symptoms of the esophagus and the upper GI tract, such as dysphagia, odynophagia, suspected gastroesophageal reflux, epigastric distress or discomfort, dyspepsia, and upper GI bleeding.

Small bowel follow-through and enteroclysis. The small bowel follow-through is a fluoroscopic procedure performed to evaluate the small bowel that requires the patient to drink a substantial volume (typically >1l) of water-soluble contrast. Examination for the clinical suspicion of Crohn's disease is still one of the most common indications.

Enteroclysis is a radiologic examination of the small intestine in which barium is infused through a transnasally placed enteric catheter with the tip positioned distal to the ligament of Treitz. Its main advantage is optimal distention of the small bowel lumen that facilitates fine delineation of mucosal detail and permits the evaluation of ulceration, small polypoid filling defects, constricting lesions, and adhesive bands. The patient discomfort, technical difficulty of placing the nasoenteric tube, and evaluation limited to only lumen are some of its shortcomings. Furthermore, small bowel follow-through and enteroclysis have been replaced to a larger extent by CT and MRI enterography, as these latter techniques evaluate not only the lumen but also the bowel wall and extraintestinal findings.

Lower GI series is a radiographic examination of the colon using single-contrast or double-contrast technique, known to have a role in the detection and evaluation of diverticular disease and inflammatory bowel disease, colon cancer screening, and evaluation of surgical anastomosis sites for stenosis and/or any leakage. Lower GI series has been replaced by colonoscopy for detecting intraluminal masses, and CT and MRI, because of their ability to detect mural and extraintestinal findings in addition to the luminal-based lesions.

US is indicated for patients presenting with signs or symptoms that may be referred from the abdomen and pelvis, especially gallbladder or female pelvis, palpable abnormalities such as abdominal masses or organomegaly, and abnormal laboratory values. US plays a major role in detecting free or loculated peritoneal and/or retroperitoneal fluid and/or blood in the emergency setting, including aortic rupture and unstable abdominal trauma. To plan for and guide an invasive procedure and follow-up of known or suspected abnormalities are other indications.

CT remains the first-line imaging modality for evaluating stable patients with abdominal trauma, detecting solid organ injury, and evaluating patients presenting with acute abdominal pain including evaluation of suspected pancreatitis, appendicitis, and diverticulitis. Bowel obstruction and abdominal aortic aneurysms are conditions that are readily assessed and diagnosed with CT. CT is also helpful in evaluating primary or metastatic malignancies, including lesion characterization, and assessing for tumor recurrence following surgical resection. CT has a role in evaluating abdominal inflammatory processes, like inflammatory bowel disease, infectious disease, and their complications such as abscess. CT enterography has a role in visualizing small bowel mucosa and has become the first-line examination in the diagnosis of Crohn's disease.

Computed tomographic colonography, also termed as virtual colonoscopy, may be used as a primary imaging modality for evaluation of colon polyps or in circumstances where colonoscopy is contraindicated.

MRI is the primary imaging modality used for the evaluation of a wide range of liver disorders. Most pancreatic diseases, especially tumors, are also well studied with MRI. In addition, this modality is also able to evaluate the full range of abdominal diseases. In general, the advantages of MRI over CT include higher soft tissue contrast resolution and safety, as it does not require ionizing radiation, thus making it most preferred examination in the evaluation of young adults and children.

Scintigraphy involves the administration of a radionuclide that transits or localizes in the salivary glands, GI tract, peritoneal cavity, or vascular system followed by gamma camera imaging. The GI scintigraphy is also often performed to assess the salivary gland function and tumors, presence and site of acute GI bleeding, and quantification of the rate of emptying from the stomach and transit through the small and large intestine.

Hepatobiliary scintigraphy has a role in the diagnosis of acute cholecystitis, evaluation of common bile duct (CBD) obstruction, and demonstration of biliary leaks.

Imaging role and workup algorithms for selected clinical scenarios

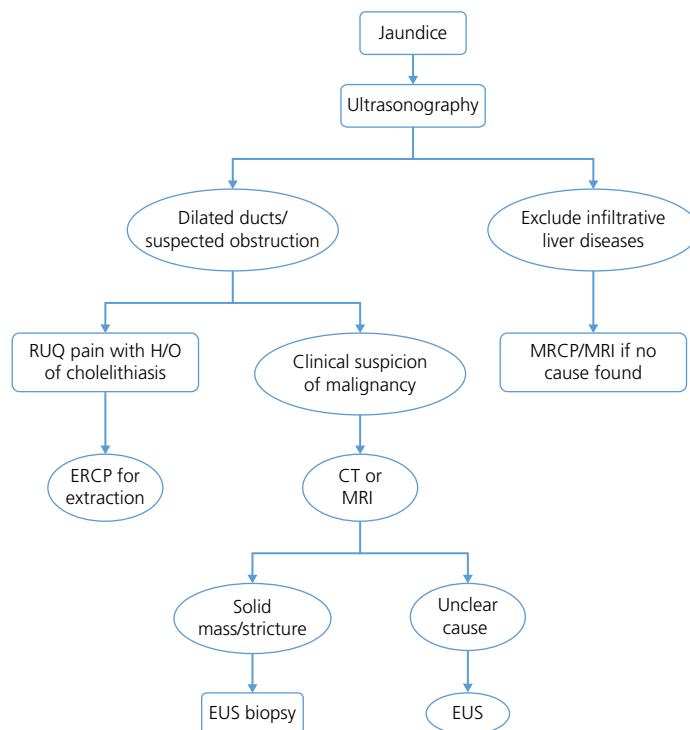
Blunt abdominal trauma

- The initial workup for hemodynamically unstable patients following blunt abdominal trauma includes chest radiographs, focused assessment with sonography for trauma (FAST) scans, and kidney-ureter-bladder abdominal radiography (KUB). Hemodynamically stable patients presenting with blunt abdominal trauma are best evaluated using MDCT with IV contrast.
- Bladder perforation or urethral injury should be ruled out in hemodynamically stable patients presenting with pelvic fracture and/or gross hematuria following a blunt or penetrating trauma to the abdomen or pelvis. This is readily performed with CT cystography after the initial assessment of the abdomen and pelvis using contrast-enhanced MDCT.

Acute GI bleeding

Upper GI bleeding from lower GI bleeding can be distinguished to a certain extent on the basis of history and nasogastric tube lavage if necessary. Refer to the imaging workup algorithm for acute GI bleeding:

- In a patient with continued GI bleeding with no identified cause on colonoscopy and endoscopy, MDCT enterography is the best imaging method to detect small obscure GI bleeding.
- Nuclear imaging and angiography are the other options considered to determine the cause of bleeding. Radionuclide scans with



CT, computed tomography; MRI, magnetic resonance imaging; RUQ, right upper quadrant pain; MRCP, magnetic resonance cholangiopancreatography; EUS, endoscopic Ultrasonography.

technetium-99m-labeled red cells are a sensitive, noninvasive technique for detecting both arterial and venous GI bleeding. However, in patients with obscure GI bleeding, it detects only if bleeding is at a rate of greater than 0.1 ml/min.

- Angiography identifies lesions with bleeding at a rate of greater than 0.5 ml/min and is superior in localizing the source of bleeding than nuclear scans, in addition to the main advantage of embolization during the time of the procedure.

Right upper quadrant pain

In the acute setting, imaging should be performed only if clinically indicated:

- CT with IV contrast provides a comprehensive assessment of the pancreas and complications related to the pancreatitis. In acutely ill patients, CT is often preferred because of its more prompt and motion-resistant data acquisition. Centers with specialized motion-resistant strategies for MRI are able to study acutely ill patients as well.
- Contrast-enhanced MRI with magnetic resonance cholangiopancreatography (MRCP) possesses higher sensitivity for detecting subtle edema or fibrotic chronic pancreatitis changes over CT.
- US is currently considered the preferred initial imaging technique for patients who are clinically suspected of having acute calculous cholecystitis. The diagnosis of acute cholecystitis is usually confirmed or excluded with ultrasonography.
- CT has higher sensitivity and specificity for the diagnosis of acute calculous cystitis but is usually reserved for doubtful cases. One limitation of CT is the consistent demonstration of CBD stones.
- MRI is overall the best imaging modality to evaluate cholecystitis because of its unmatched ability to show acute calculous and acalculous cholecystitis and importantly because of the outstanding evaluation of the CBD and intrahepatic biliary tree; however, the lack of widespread availability of MRI and the

relatively high cost prohibit its primary use in patients with acute calculous cholecystitis.

- Scintigraphy has a high sensitivity and specificity in patients who are suspected of having acute cholecystitis and is occasionally used. Due to a combination of reasons, including drawbacks, broad imaging capability, and clinician referral pattern, its use is limited in clinical practice.

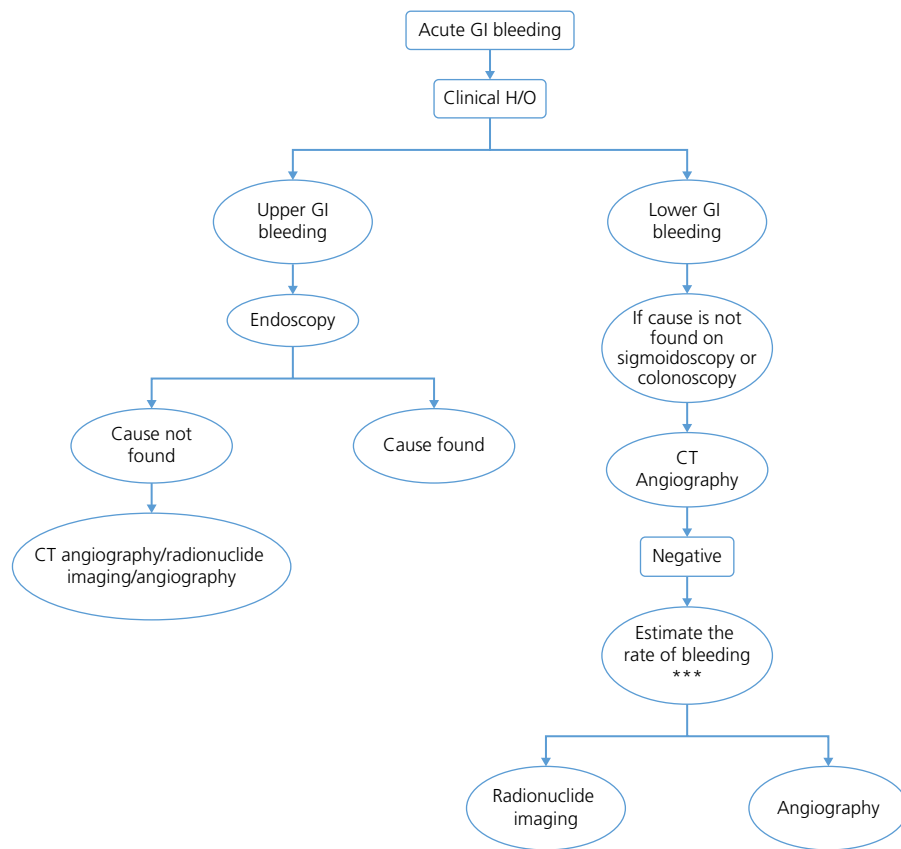
Right lower quadrant pain

Appendicitis can be clinically diagnosed; however, sensitivity and specificity for diagnosis are substantially increased by imaging, reducing the number of white appendectomies. Refer to the imaging workup algorithm for right lower quadrant pain:

- CT is the most accurate imaging modality for evaluating suspected appendicitis and alternative etiologies of right lower quadrant abdominal pain.
- In children and thin adults, US is the preferred initial examination, as it is nearly as accurate as CT for diagnosis of appendicitis while avoiding the exposure to ionizing radiation. In pregnant women, MR is the examination of choice. At experienced centers, MRI is an excellent test to study appendicitis in all subjects.

Left lower quadrant pain

- Female patients of reproductive age group are evaluated with transabdominal pelvic US with or without transvaginal US.
- CT is most commonly used for evaluating suspected acute diverticulitis for its high sensitivity and specificity, its ability to define the presence and extent of disease that might need a percutaneous catheter drainage or surgery, and its ability to show any associated extracolonic diseases.
- MRI has similar features to CT and shows inflammation with similar sensitivity.



CT, computed tomography.

Jaundice

The primary aim of imaging in jaundice is to detect whether there is a mechanical obstruction of the bile ducts. Refer to the imaging workup algorithm for jaundice:

- US is usually the first-line modality that helps to determine bile duct dilatation and to confirm or exclude the presence of stones.
- If there is ductal dilatation with a high suspicion for stone disease associated with right upper quadrant pain, MRI and MRCP may be performed as the second modality.
- If there is ductal dilatation with a high suspicion of malignancy, then MRI with MRCP or CT with thin reconstructions is helpful in defining the point of obstruction, assessing for resectability, and staging a metastatic disease.
- If no mechanical cause for jaundice is identified by the first-line modality of US with no dilatation of the ducts, it is important to exclude infiltrative hepatocellular disease before performing invasive testing such as liver biopsy. The superior tissue characterization offered by MRI in this situation may help further the diagnosis and help direct biopsy.

Pancreatic cancer

The selection of appropriate candidates for potentially curative surgical resection is the major role of imaging in the patients newly diagnosed with pancreatic cancer:

- Overall, the imaging technique that is best able to detect and stage pancreatic cancers, especially the most important ones, small potentially surgically curative, is high-quality MRI on state-of-the-art MR equipment.
- CT is a method that is most often used in the setting of pancreatic cancer but may miss small potentially curable cancers.

- Endoscopic US (EUS) is an excellent method to confirm a mass lesion, best suited for evaluation of the head of the pancreas, but also dependent on local resources and expertise.

Colorectal cancer

Staging processes for colon cancer and rectal cancer are different. In colon cancer, regional staging is indicated only when advanced disease is suspected:

- In colon cancer, CT/US/MR of the abdomen and chest XR/chest CT may be performed if surgical or management decisions are likely to change.
- In rectal cancer, accurate preoperative staging is indicated, as chemoradiotherapy has been proved to be effective in certain groups of the population.
- MRI and endorectal US are the preferred methods to evaluate the rectal wall and invasion of the mesorectal fascial envelope; however, MRI has the advantage to better define the presence of perirectal and iliac lymph nodes.

Genitourinary system

X-ray kidneys, ureters, and bladder (KUB). X-ray kidneys, ureters, and bladder also known as X-ray KUB is rarely used nowadays to evaluate for presence of stones, as noncontrast CT is overwhelmingly superior in detecting stones. The KUB may be used as a follow-up to evaluate the changes in stones that have been localized on CT. KUB may be used to determine the positioning of indwelling devices such as ureteral stents, central lines, and catheters.

Intravenous urogram (IVU). An IVU is a radiographic study that allows to study both anatomic and functional information of