MUSCULOSKELETAL X-RAYS
FOR MEDICAL STUDENTS AND TRAINEES

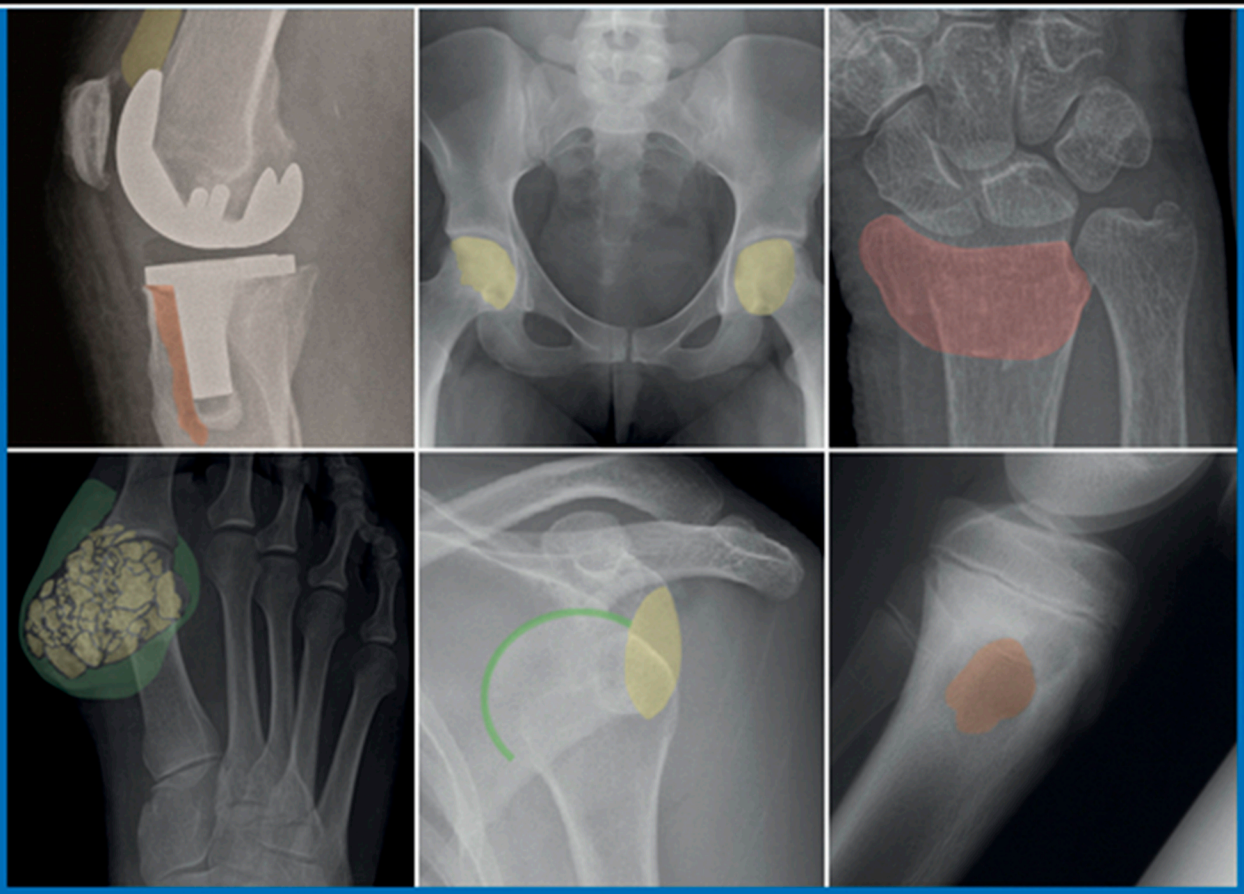

ANDREW K BROWN & DAVID G KING

with self-test

WILEY Blackwell

Musculoskeletal X-rays

for Medical Students and Trainees

This title is also available as an e-book.
For more details, please see
www.wiley.com/buy/9781118458730
or scan this QR code:

Musculoskeletal X-rays
for Medical Students and Trainees

Andrew K. Brown
Consultant Rheumatologist
York Teaching Hospital NHS Trust; and
Senior Lecturer in Medical Education and Rheumatology
Hull York Medical School

David G. King
Consultant Musculoskeletal Radiologist
York Teaching Hospital NHS Trust; and
Honorary Senior Lecturer
Hull York Medical School

WILEY Blackwell

This edition first published 2017 © 2017 by John Wiley & Sons, Ltd.

Registered Office
John Wiley & Sons, Ltd, The Atrium, Southern Gate, Chichester, West Sussex, PO19 8SQ, UK

Editorial Offices
9600 Garsington Road, Oxford, OX4 2DQ, UK
The Atrium, Southern Gate, Chichester, West Sussex, PO19 8SQ, UK
350 Main Street, Malden, MA 02148-5020, USA

For details of our global editorial offices, for customer services and for information about how to apply for permission to reuse the copyright material in this book please see our website at www.wiley.com/wiley-blackwell

The right of the authors to be identified as the authors of this work has been asserted in accordance with the UK Copyright, Designs and Patents Act 1988.

All rights reserved. No part of this publication may be reproduced, stored in a retrieval system, or transmitted, in any form or by any means, electronic, mechanical, photocopying, recording or otherwise, except as permitted by the UK Copyright, Designs and Patents Act 1988, without the prior permission of the publisher.

Designations used by companies to distinguish their products are often claimed as trademarks. All brand names and product names used in this book are trade names, service marks, trademarks or registered trademarks of their respective owners. The publisher is not associated with any product or vendor mentioned in this book. It is sold on the understanding that the publisher is not engaged in rendering professional services. If professional advice or other expert assistance is required, the services of a competent professional should be sought.

The contents of this work are intended to further general scientific research, understanding, and discussion only and are not intended and should not be relied upon as recommending or promoting a specific method, diagnosis, or treatment by health science practitioners for any particular patient. The publisher and the author make no representations or warranties with respect to the accuracy or completeness of the contents of this work and specifically disclaim all warranties, including without limitation any implied warranties of fitness for a particular purpose. In view of ongoing research, equipment modifications, changes in governmental regulations, and the constant flow of information relating to the use of medicines, equipment, and devices, the reader is urged to review and evaluate the information provided in the package insert or instructions for each medicine, equipment, or device for, among other things, any changes in the instructions or indication of usage and for added warnings and precautions. Readers should consult with a specialist where appropriate. The fact that an organization or Website is referred to in this work as a citation and/or a potential source of further information does not mean that the author or the publisher endorses the information the organization or Website may provide or recommendations it may make. Further, readers should be aware that Internet Websites listed in this work may have changed or disappeared between when this work was written and when it is read. No warranty may be created or extended by any promotional statements for this work. Neither the publisher nor the author shall be liable for any damages arising herefrom.

Library of Congress Cataloging-in-Publication Data

Names: Brown, Andrew K., author. | King, David G., author.
Title: Musculoskeletal X-rays for medical students and trainees / Andrew K. Brown, David G. King.
Description: Chichester, West Sussex, UK ; Malden, MA : John Wiley & Sons Inc., 2015. | Includes bibliographical references and index. | Description based on print version record and CIP data provided by publisher; resource not viewed.
Identifiers: LCCN 2014040930 (print) | LCCN 2014040575 (ebook) | ISBN 9781118458716 (Adobe PDF) | ISBN 9781118458723 (ePub) | ISBN 9781118458730 (pbk.)
Subjects: | MESH: Musculoskeletal Diseases–radiography.
Classification: LCC RC925.7 (print) | LCC RC925.7 (ebook) | NLM WE 141 | DDC 616.7/07572–dc23
LC record available at http://lccn.loc.gov/2014040930

A catalogue record for this book is available from the British Library.

Wiley also publishes its books in a variety of electronic formats. Some content that appears in print may not be available in electronic books.

Cover images: © Andrew K. Brown and David G. King

Set in 10/13pt Frutiger by SPi Global, Pondicherry, India

1 2017

Contents

Preface, vii

Acknowledgements, viii

Part 1: Introduction, 1

1 Musculoskeletal X-rays, 3

Introduction, 3
Basic principles of requesting plain radiographs of bones and joints, 4
Basic principles of examining and reporting plain radiographs of bones and joints, 6
Normal anatomy on musculoskeletal X-rays, 8

Part 2: Pathology, 21

2 Trauma, 23

Bone and joint injuries, 23
Specific injuries, 41
Spine, 58
Paediatric fractures, 67
Fractures in child abuse, 73
Further reading, 76

3 Arthritis, 77

Osteoarthritis, 77
Rheumatoid arthritis, 80
Crystal arthropathy, 83
Gout, 83
Calcium pyrophosphate disease, 86
Psoriatic arthritis, 91
Axial spondyloarthritis (ankylosing spondylitis), 95

4 Tumours and tumour-like lesions, 98

Radiological evaluation of the patient, 98
X-rays – general principles, 101
Malignant tumours, 105
Bone metastases, 105
Multiple myeloma, 107
Plasmacytoma, 108
Osteosarcoma, 110
Chondrosarcoma, 111
Ewing's sarcoma, 113
Benign tumours, 114
Exostosis (Osteochondroma), 115

Osteoid osteoma, 116
Tumour-like lesions, 117
Simple bone cyst, 118
Infection, 119

5 Metabolic bone disease, 120
Osteoporosis, 120
Osteomalacia, 121
Hyperparathyroidism, 122
Chronic kidney disease metabolic bone disorder, 124
Haemochromatosis, 126

6 Infection, 128
Routes of spread, 128
Causative organisms, 128
Osteomyelitis, 129
Septic arthritis, 134
Infective discitis, 136

7 Non-traumatic paediatric conditions, 138
Developmental dysplasia of the hip, 138
Perthes' disease, 140
Tarsal coalition, 141
Osteochondritis dissecans, 143

8 Other bone pathology, 144
Paget's disease of bone, 144
Hypertrophic Osteoarthropathy (HOA), 147
Avascular necrosis, 147

9 Joint replacement, 149
Hardware failure and aseptic loosening, 149
Infection, 154
Malalignment and instability, 155
Periprosthetic fracture, 156

Part 3, 157

Self-assessment questions, 159

Self-assessment answers, 172

Index, 185

Preface

X-rays of bones and joints play a central role in musculoskeletal medicine and surgery, but the approach to evaluation and interpretation of X-rays is not always well taught or easily understood. This book should provide greater insight into the mysteries of the plain film X-ray and is ideal for medical students, doctors in training, physiotherapists, nurse practitioners and radiographers.

The book covers radiological anatomy as well as the main areas of pathology in which plain film assessment is clinically useful. The importance of correlation with relevant clinical findings and other imaging modalities will be highlighted and discussed where appropriate.

To make the radiological signs clear, each illustration consists of a pair of images, the first a standard X-ray and the second with coloured overlays added to precisely define each abnormality. By covering up the second image, the reader can also use this format to practise X-ray interpretation.

Our approach is largely based on the authors' combined experience of teaching medical students, trainees in emergency medicine, orthopaedics and rheumatology, as well as professions allied to medicine, over many years. By using this book, the reader will learn how the clues or signs found on an X-ray can be extracted and put together to aid in making a diagnosis and informing disease management.

We hope this book will provide an interesting and enjoyable way to obtain a clearer understanding of X-rays from the basics to more subtle findings across a broad range of musculoskeletal medicine.

Andrew K. Brown
David G. King

Acknowledgements

We would like to thank our colleagues at York Teaching Hospital for their help with finding suitable images for this book and especially Mike Pringle in the Department of Medical Illustration and Photography for his help and advice. We are also grateful to the students of Hull York Medical School for acting as subjects while we were developing our ideas and the material for this book.

PART 1
Introduction

1 Musculoskeletal X-rays

Introduction

Despite the availability of a wide range of imaging techniques to visualise musculoskeletal structures, plain radiographs or X-rays remain an important and widely used first-line investigation. It is probably the most readily available and least expensive imaging modality and is easily accessible to patients and healthcare professionals. As such, all medical professionals require at least a basic level of knowledge and training in the fundamental principles of requesting, interpreting and reporting plain radiographs of bones and joints.

Musculoskeletal X-rays for Medical Students and Trainees, First Edition. Andrew K. Brown and David G. King.
© 2017 John Wiley & Sons, Ltd. Published 2017 by John Wiley & Sons, Ltd.

Basic principles of requesting plain radiographs of bones and joints

Which structures?

Before requesting an X-ray, the clinician should already have a good idea of the likely nature of the clinical problem and which musculoskeletal structures may be affected and what may or may not be visualised on an X-ray. For example, radiographs are best at detecting pathological changes in bones, joints and cartilage, such as joint space narrowing, fracture, subluxation and dislocation. However, many soft tissue structures such as ligaments, tendons and synovium are not well visualised, and alternative imaging may be more appropriate to provide additional useful information to aid diagnosis and treatment.

Clinical assessment including the patient's symptoms and a physical examination will usually determine the site or region that is to be evaluated by X-ray. Exceptions may include a patient with rheumatoid arthritis where X-rays of both hands and feet may be used to evaluate the extent of disease or structural damage which may be repeated serially to compare any disease progression over time.

Which views?

It is important to consider which views are chosen to visualise a particular region of interest. This is because the X-ray beam creates a two dimensional shadow of a structure so selecting the correct view will maximise sensitivity. A basic principle is that two views should be requested, ideally 90° apart, which are usually obtained in antero-posterior (AP) and lateral or oblique views. This is particularly important in a trauma context where fracture or dislocation may be missed if only a single view is acquired but may be less important for the assessment of arthritis. There are a number of established techniques and protocols for optimal image acquisition using standardised views of most musculoskeletal sites. Specialist views may also be considered in particular clinical situations, such as a 'skyline view' for the patello-femoral joint or 'through-mouth view' for the cervical spine. As well as the particular plane used to acquire the radiographic image, the position of the patient should also be considered. For example, weight-bearing views with the patient in a standing position are often much more informative in evaluating cartilage loss in the knees of a patient with osteoarthritis or in providing additional information concerning biomechanical changes in the feet.

Compare both sides and review previous images

Particularly in equivocal cases, it may be informative to compare findings in a symptomatic area with the same region on the opposite side of the body or to look at the same region on a previous X-ray. For example, in a patient with hip pain, an AP X-ray of the pelvis allows some comparison between both hip joints, or in a patient with rheumatoid arthritis, comparison with a previous X-ray of the hands allows interpretation of any progression of erosive joint damage.

Correlation with clinical and other imaging findings

Any X-ray findings always need to be interpreted in clinical context, with an individual's symptoms, clinical examination findings and any other investigation results in mind. It may be necessary to perform additional imaging using alternative techniques such as ultrasound, computed tomography or magnetic resonance imaging, which may offer important additional or confirmatory information. Discussion with a specialist musculoskeletal radiologist is frequently helpful, and sharing and reviewing more challenging cases at a musculoskeletal radiology meeting involving clinicians and radiologists are often productive.

Safety considerations

Whilst undertaking a radiographic assessment is a well-regulated process and is generally considered safe, it is important to remember that the procedure exposes a patient to ionising radiation and a number of important safety precautions need to be considered. This is particularly important in children and young adults and when the area includes any organ which is more sensitive to ionising radiation such as the thyroid, breasts or gonads. In women of childbearing age if the area involves the abdomen, spine or pelvis, it is essential to ask the patient about the possibility of pregnancy and an X-ray in these circumstances should only be performed if absolutely necessary, such as a suspected pelvic fracture.

The amount of radiation exposure varies depending on the structure being visualised. Radiographs of deeper structures, such as the pelvis or lumbar spine, subject the patient to considerably greater radiation exposure than that of more peripheral structures, such as an examination of a single limb joint. The number of views and images obtained are proportional to the amount of radiation received. In all circumstances, it is important to be able to justify any radiation exposure on the basis of potential risk and benefit. The Department of Health Policy on Ionising Radiation (Medical Exposure) Regulations 2000 [1] covers these aspects in detail.

Basic principles of examining and reporting plain radiographs of bones and joints

Everyone should have a straightforward strategy for reviewing and interpreting musculoskeletal X-rays, including some basic principles and a systematic approach that can be routinely followed. It can often feel intimidating to review, interpret and describe an X-ray, but this need not be complex or jargon-heavy and confident use of simple descriptive language is all that is required. Undoubtedly, knowledge of musculoskeletal anatomy and understanding of pathological processes affecting bone, cartilage, joints and soft tissues will help, but a lot of information can be gained from describing any obvious abnormal or different appearances using simple descriptions, words and phrases. Even if you see an abnormality, it is still important to continue to evaluate the whole X-ray in case other findings are present. If an obvious change is not present or immediately apparent, then it is useful to be able to fall back on a standard framework with which to organise your thoughts and report your observations. An example of such an approach is outlined as follows:

1. *Check patient identification details and labelling*.
   Do the patient and X-ray identification details correspond, is it the correct X-ray being viewed, date and time, left or right?
2. *Is the image quality satisfactory? Are imaging angles optimal?*
   Consider densities, penetration and blackening of film (see "X-ray densities" below) and any inappropriate rotation and viewing angles. Also consider all additional views and patient position, has the region of interest been included?

X-ray densities

To understand the appearance of different densities on an X-ray, it is useful to consider the basic concept of how it has been produced. The image is essentially a shadow made by sending X-rays through an area of the body onto a detector behind. For about 100 years, the detector used was film. More recently, film has been swapped for electronic digital detectors but the concept remains the same. Where there is only air between the X-ray source and the detector, such as in the area around a limb, the film will be very exposed, that is blackened. Dense structures, such as bone, will stop most X-rays and the film will be less exposed, that is more white. Soft tissues produce intermediate shades of grey.

Assuming there is no metallic foreign body or other man-made artefact, there are only four densities to think about on an X-ray: calcium is white and gas is black. Of the soft tissues, fat is a darker shade of grey because it is a little less dense to X-rays than other soft tissues. All other soft tissues are the same lighter shade of grey, as is fluid (see Figure 1.1).

3. *Describe any obvious abnormality using simple descriptive language*.
   Name the specific bone (e.g. right tibia) and describe the location of any abnormality (e.g. proximal, middle or distal; head, neck or shaft; cortex or medulla). Basic terminology used for the paediatric and adult skeleton is shown in Figure 1.2. A combination of these terms and specific anatomical names should be used.
4. *Use a systematic approach to consider specific musculoskeletal structures (bones, joints, cartilage and soft tissues)*.
   - Bone alignment – are there any changes in position which may suggest a fracture or dislocation?
   - Bone cortices – follow the outline of each bone as any breach in the cortex may indicate a fracture or an erosive arthritis.
   - Bone texture – Altered density or disruption in the usual trabecular pattern within the substance of the bone may indicate pathology.
   - Joint and cartilage – a careful look at the joint space may demonstrate changes such as joint space narrowing due to cartilage loss or calcification of the cartilage (chondrocalcinosis) or new bone formation (e.g. osteophytes in osteoarthritis).

- Soft tissues – remember to look at the soft tissues as well as the bones as they can hold helpful clues. For example, it may be possible to see if joint swelling is present and, therefore, that there must be something significant wrong with that joint. This will be discussed further in the chapter on trauma but also applies to any cause of joint swelling.

5. *Review all views and X-ray images, compare both sides and adjacent joints and re-examine any previous imaging.*
6. *Always consider clinical findings and correlation with other imaging and test results.*
7. *If there is still uncertainty, review all the available information once more, discuss the case with a musculoskeletal radiologist, and consider reviewing the case at a multidisciplinary radiology conference.*

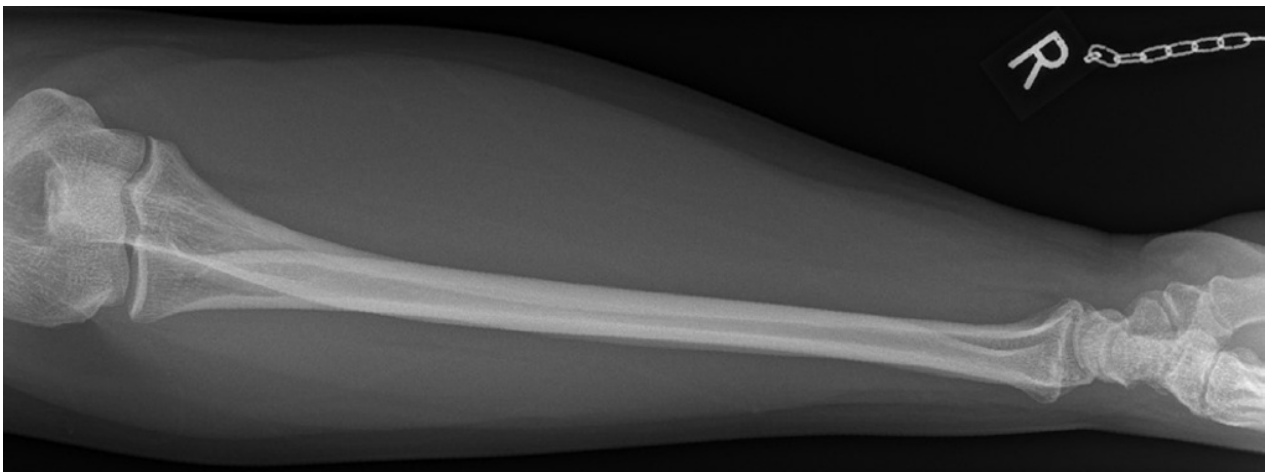

Figure 1.1 X-ray of the forearm illustrating the naturally occurring densities in a patient. White = calcium (in bone), dark grey = fat, lighter grey = all other soft tissue structures. Surrounding air is black.

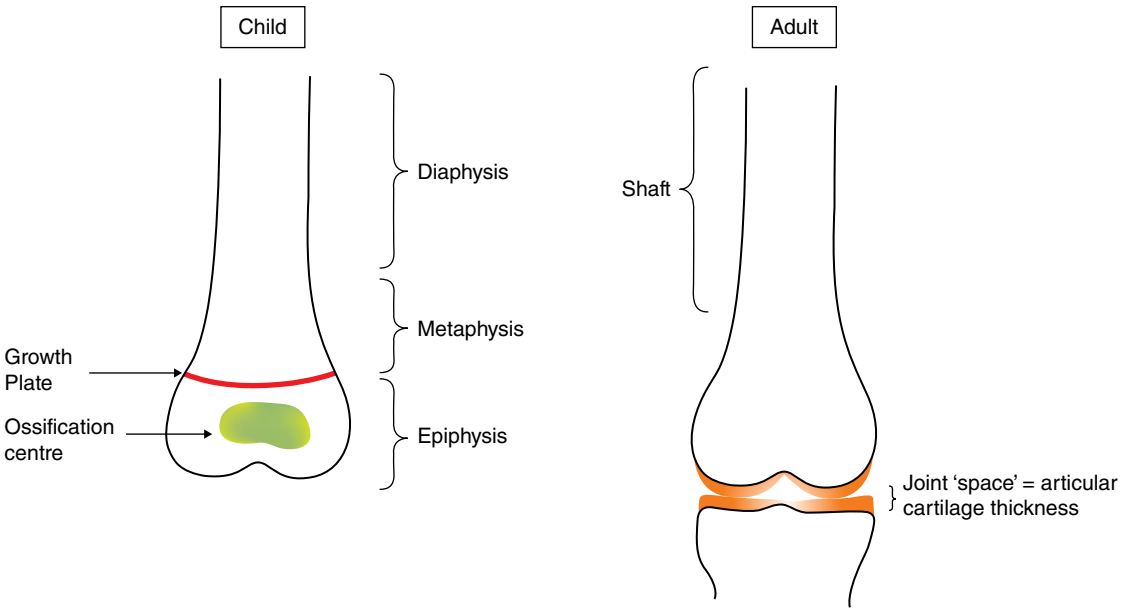

Figure 1.2 Recommended terminology for describing bone anatomy in adults and children.

Normal anatomy on musculoskeletal X-rays

This section features a series of paired standard X-ray images of each region, annotated with important anatomical structures. It will be useful to refer back to these as you read through the remaining chapters.

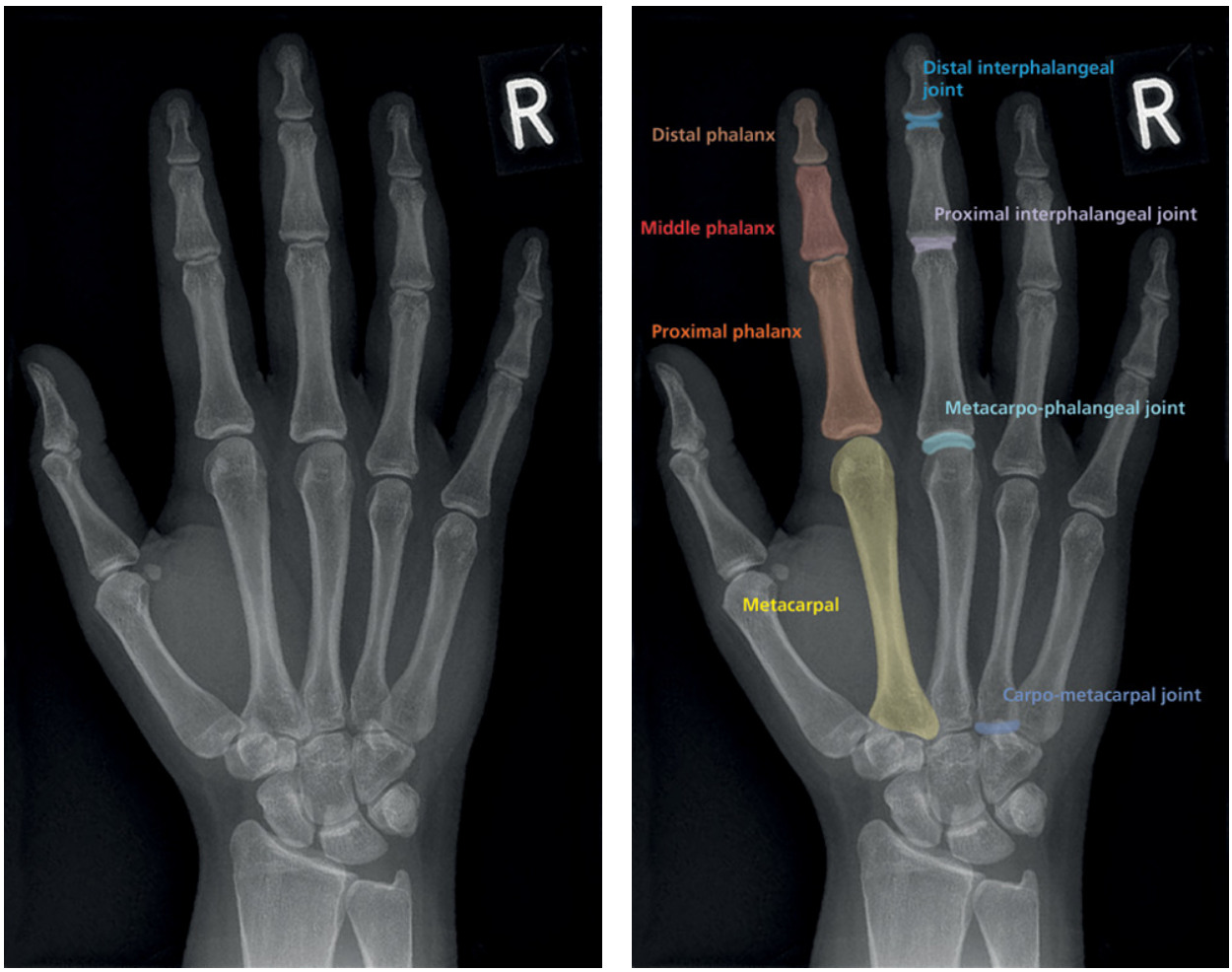

Figure 1.3 Normal hand.

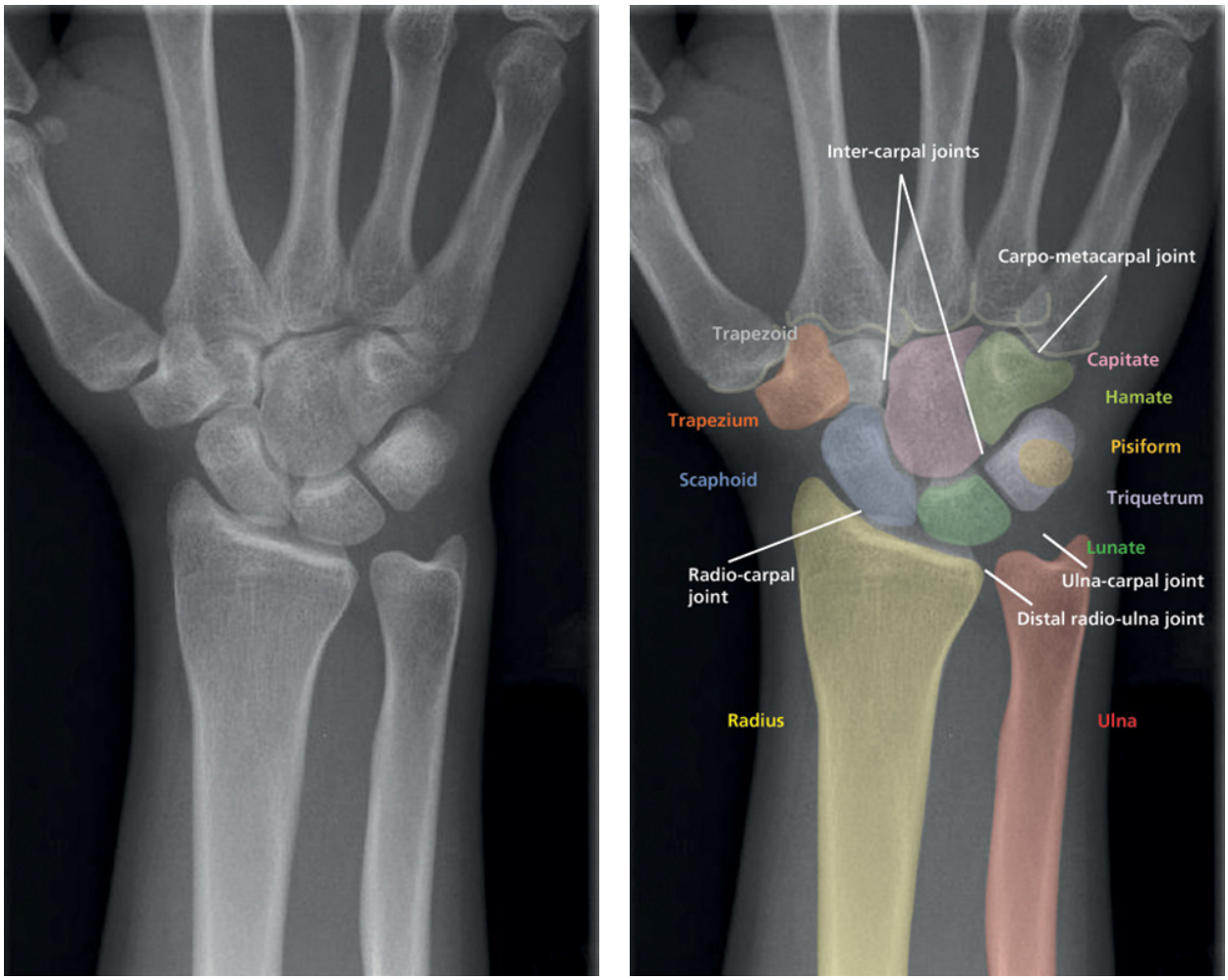

Figure 1.4 Normal wrist, PA view.

Remember trapez*ium* is adjacent to the th*um*b.

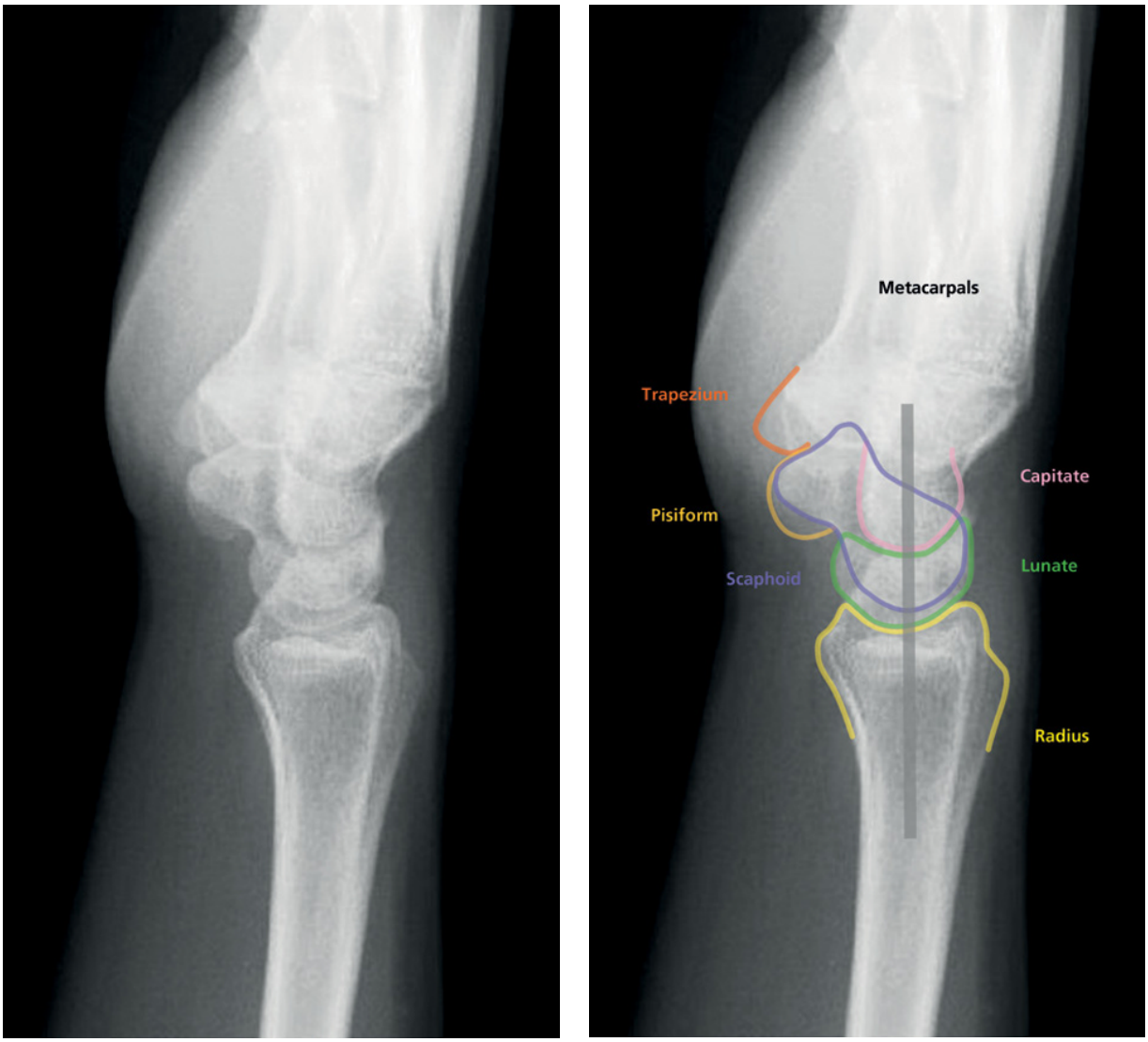

Figure 1.5 Normal wrist, lateral view (see the 4 Cs in Chapter 2).