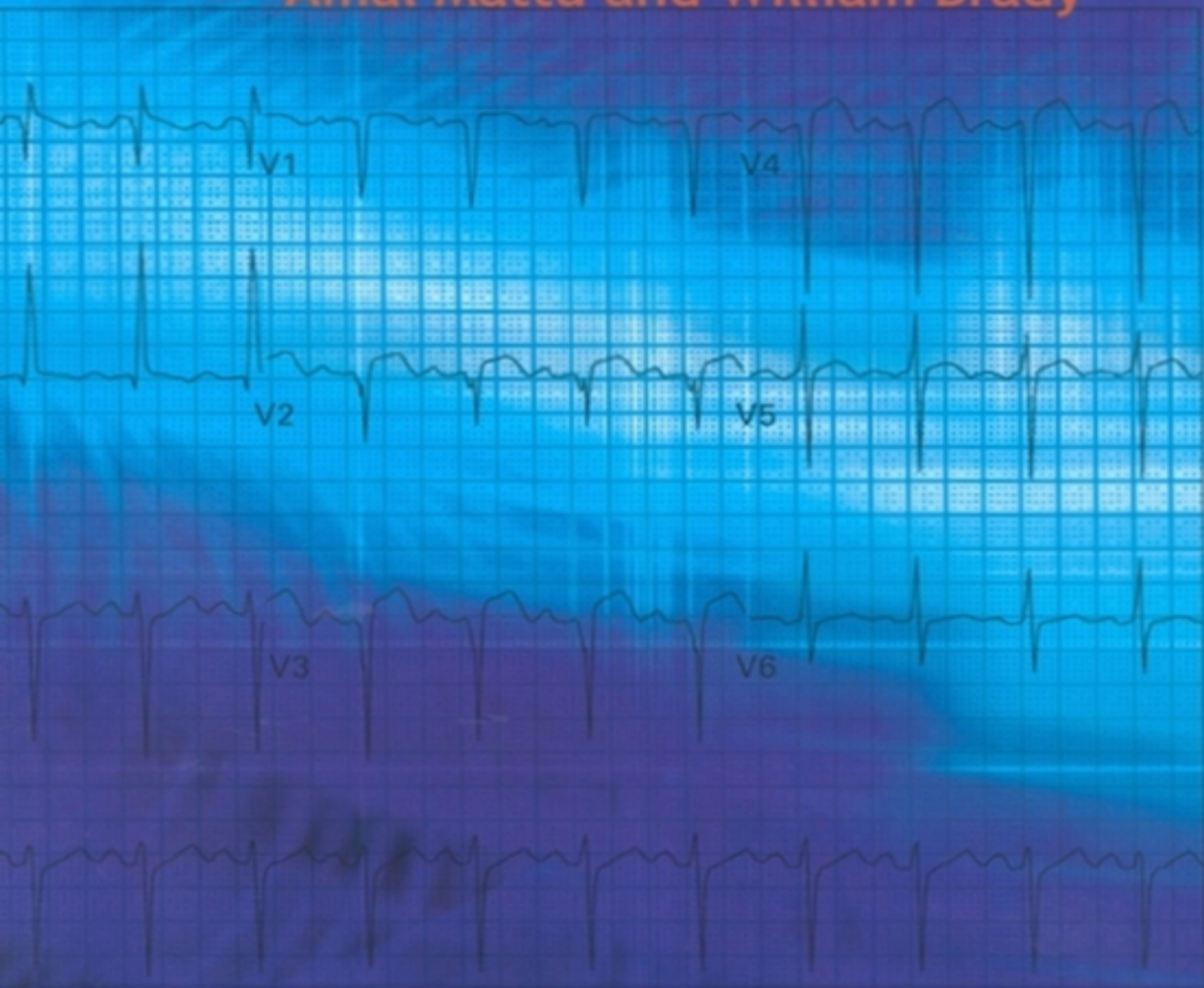


ECGs for the Emergency Physician **1**

Amal Mattu and William Brady



Blackwell
Publishing

Contents

[Foreword](#)

[Preface](#)

[Dedications](#)

Part 1

[Case histories](#)

[ECG interpretations and comments](#)

Part 2

[Case histories](#)

[ECG interpretations and comments](#)

[Appendix A: Differential diagnoses](#)

[Appendix B: Commonly used abbreviations](#)

[Index](#)

ECGs for the Emergency Physician

Amal Mattu

*Director, Emergency Medicine Residency Program, Co-Director, Emergency Medicine/Internal Medicine
Combined Residency Program, University of Maryland School of Medicine, Baltimore, Maryland, USA*

William Brady

*Associate Professor, Vice Chair, and Program Director, Department of Emergency Medicine
University of Virginia Health System, Charlottesville, Virginia, USA
and
Medical Director, Charlottesville-Albermarle Rescue Squad, Charlottesville, Virginia, USA*

BMJ
Books

© BMJ Publishing Group 2003

BMJ Books is an imprint of the BMJ Publishing Group

All rights reserved. No part of this publication may be reproduced, stored in a retrieval system, or transmitted, in any form or by any means, electronic, mechanical, photocopying, recording and/or otherwise, without the prior written permission of the publishers.

First published in 2003

by BMJ Books, BMA House, Tavistock Square,

London WC1H 9JR

www.bmjbooks.com

British Library Cataloguing in Publication Data

A catalogue record for this book is available from the British
Library

ISBN 0 7279 1654 8

Foreword

There has been a great need for a user friendly ECG text that fills the void between an introductory text designed for students and an advanced reference source for cardiologists. *“ECGs for the Emergency Physician”* fills this void. It is an ECG teaching and reference textbook for acute and emergency care physicians written by two specialists practicing and teaching acute and emergency care.

Drs Mattu and Brady have created an ECG text that facilitates self instruction in learning the basics, as well as the complexities, of ECG interpretation. They know that ECG interpretation requires knowledge, insight and practice. They know “the eye does not see, what the mind does not know.” In order to accomplish this goal of teaching ECG interpretation, they have divided their book into two parts. In Part I, as the authors state, are the “bread and butter” ECGs of acute care. These are the ECG findings that form the core knowledge necessary for accurate ECG interpretation. In Part II they teach recognition of more subtle ECG abnormalities, which when mastered, allow the practitioner to become an expert.

The beauty of this text lies in the combining of a collection of emergency department ECGs with the authors’ insights and expert observations. This book has great utility as a reference text, a bound ECG teaching file, a board review aide or a resident in emergency medicine’s best friend for learning the art of advanced ECG interpretation. Its greatest value however, is for all of us who want to be both challenged and taught by 200 great electrocardiograms and their interpretations.

May the forces be with you.

Corey M Slovis
Professor of Emergency Medicine and Medicine
Chairman, Department of Emergency Medicine
Vanderbilt Medical Center
Nashville, Tennessee
Medical Director Metro Nashville Fire EMS

Preface

Emergency and other acute care physicians must be experts in the use and interpretation of the 12-lead electrocardiogram (ECG). We have prepared this text with this basic though highly important thought in mind. This text represents our effort to further the art and science of electrocardiography as practiced by emergency physicians and other acute care clinicians.

A significant number of the patients managed in the emergency department and other acute care settings present with chest pain, cardiovascular instability, or complaints related to the cardiovascular system. The known benefits of early, accurate diagnosis and rapid, appropriate treatment of cardiovascular emergencies have only reinforced the importance of physician competence in electrocardiographic interpretation. The physician is charged with the responsibility of rapid, accurate diagnosis followed by appropriate therapy delivered expeditiously. This evaluation not infrequently involves the performance of the 12-lead ECG. For example, the patient with chest pain presenting with ST-segment elevation, acute myocardial infarction must be rapidly and accurately evaluated so that appropriate therapy is offered in prompt fashion. Alternatively, the hemodynamically unstable patient with atrioventricular block similarly must be cared for in a rapid manner. In these instances as well as numerous other scenarios, resuscitative and other therapies are largely guided by information obtained from the ECG.

The electrocardiogram is used frequently in the emergency department (ED) and other acute care settings; numerous presentations may require a 12-lead electrocardiogram. For instance, the most frequent indication for ECG performance in the ED is the presence of

chest pain; other complaints include dyspnea and syncope. Additional reasons for obtaining an ECG in the ED include both diagnosis-based (acute coronary syndrome, suspected pulmonary embolism, and the “dysrhythmic” patient) and system-related indications (for the “rule-out myocardial infarction” protocol, for admission purposes, and for operative clearance).¹ Regardless of the cause, the physician must be an expert in the interpretation of the 12-lead ECG. Interpretation of the ECG is as much an art as it is a science. Accurate ECG interpretation requires a sound knowledge of the electrocardiogram, both the objective criteria necessary for various diagnoses of those patients encountered in the ED as well as a thorough grasp of the various electrocardiographic waveforms and their meaning in the individual patient.

We have prepared this text for the physician who manages patients not only in the ED but also in other acute care settings - whether it be in the office, the hospital ward, critical care unit, the out-of-hospital arena, or other patient-care locale. We have used actual ECGs from patients treated in our EDs; a brief but accurate history has also been provided in each instance. In certain cases, the history may provide a clue to the diagnosis yet in other situations the clinical information will have no relationship to the final diagnosis - as is the case in the ED. We have made an effort to choose the most appropriate ECG from each patient, but as occurs in “real ED,” some of the ECGs are imperfect: the evaluation is hindered by artifact, incomplete electrocardiographic sampling, etc. We have also provided the ECGs in a random fashion, much the way actual patients present to the emergency department. We have endeavored to reproduce the reality of the ED when the reader uses this text to expand their knowledge of the 12-lead electrocardiogram and how it relates to patient care.

The reader is advised to read the clinical history provided for each ECG and then, much as the clinician would interpret the electrocardiogram in the ED, review the 12-lead ECG. After a clinically focused review of the ECG, the reader is then able to review the interpretation. This ECG text has been constructed in two basic sections. The first half of the text contains ECGs that we feel represent the “bread and butter” of emergency electrocardiography – the core material with which we feel that the acute care physician must be thoroughly familiar. These ECGs were chosen because they represent common electrocardiographic diagnoses that all emergency physicians should know. This section is prepared primarily for the physician-in-training (for example, the emergency medicine resident) though practicing physicians will also benefit from reviewing the material. The second half of the text is composed of ECGs that are more challenging. The electrocardiographic diagnoses are more difficult to establish and will often be on subtle findings. In some cases, the ECGs in this section were chosen not necessarily because of the related level of difficulty but because of subtle teaching points found, which are likely to be beyond the level of the physician-in-training.

It is also crucial to understand that this text is not intended for the “beginner in ECG interpretation”. The text, **in essence an electrocardiographic teaching file**, is intended for the physician who possesses a sound, basic understanding of electrocardiography yet desires additional practice and review – a review which is highly clinically pertinent. The electrocardiography beginner is advised to begin by reading through one of the many outstanding books that have previously been written for novice students prior to studying this teaching file.

One last point must also be stressed to the reader of this text. Diagnostic criteria for various electrocardiographic

diagnoses vary somewhat amongst authors. Therefore, in an effort to standardize the interpretations used in this text, we chose to use the following two references as the “gold standard” for electrocardiographic interpretations: Chou and Knilans' *Electrocardiography in Clinical Practice: Adult and Pediatric* and Galen's *Marriott's Practical Electrocardiography*.^{2,3}

References

1. Brady W, Adams M, Perron A, Martin M. The impact of the 12-lead electrocardiogram in the evaluation of the emergency department patient. *Ann Emerg Med* (accepted for publication/publication pending).
2. Chou T-C, Knilans TK. *Electrocardiography in Clinical Practice: Adult and Pediatric 4th edn*. Philadelphia, PA:WB Saunders Company, 1996.
3. Galen SW. *Marriott's Practical Electrocardiography 10th edn*. Philadelphia, PA: Lippincott Williams & Wilkins, 2001.

Dedications

This work is dedicated to my wife, Sejal, for her tremendous patience and never-ending support; to my son, Nikhil, for constantly reminding me of the priorities in life; to the Emergency Department staff at Mercy Medical Center in Baltimore for their friendship and their ECG contributions; to the faculty and residents of the University of Maryland Emergency Medicine Residency Program for providing the main inspiration for this work; to Mary Banks and BMJ Books for supporting and believing in this work; to Dr Bill Brady for his mentorship, friendship, and commitment to teaching and education; and to emergency physicians around the world – may your dedication to learning continue to strengthen our specialty and improve patient care.

Amal Mattu

Director, Emergency Medicine Residency Program
Co-Director, Emergency Medicine/Internal Medicine
Combined Residency Program
University of Maryland School of Medicine
Baltimore, Maryland
USA

I would like to thank my wife, King, for her love, support, wise counsel, and patience – none of this effort would be possible without her; my children, Lauren, Anne, Chip, and Katherine, for being wonderful and my primary inspiration; my parents, Bill and Joann Brady, for all that they have done and continue to do; the Emergency Medicine Residents (past, present, and future) at the University of Virginia, for their hard work, astronomical dedication, and inspiration – all directed at our patients and the specialty of Emergency Medicine; Dr Marcus Martin, Chair of Emergency Medicine at the University of Virginia, for his support, guidance, and mentorship; and my co-author, Dr Amal Mattu, for his dedicated effort on this book in particular and his dedication

to Emergency Medicine education in general - a true gentleman, talented clinician, and distinguished scholar

William Brady

Associate Professor, Vice Chair, and Program Director

Department of Emergency Medicine

University of Virginia Health System

Charlottesville, Virginia

USA

and

Medical Director, Charlottesville-Albermarle

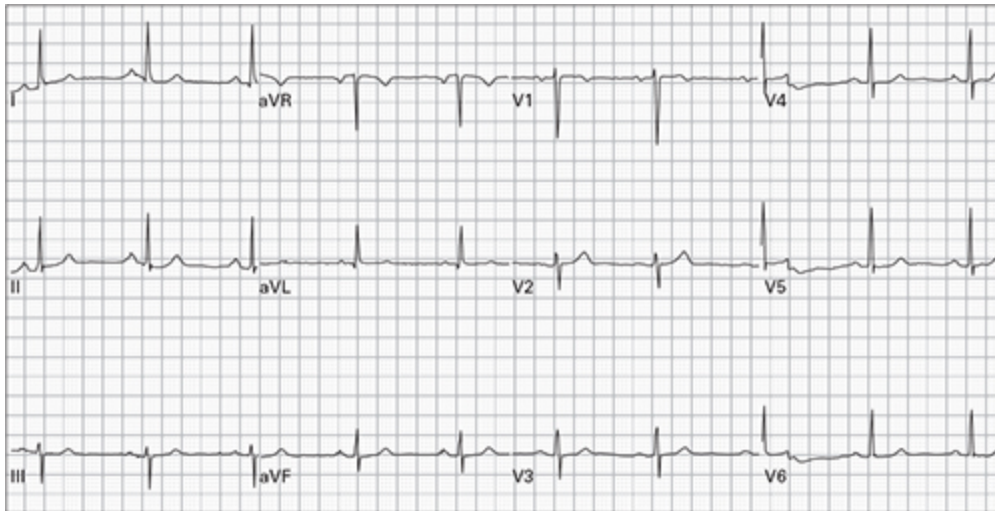
Rescue Squad, Charlottesville, Virginia,

USA

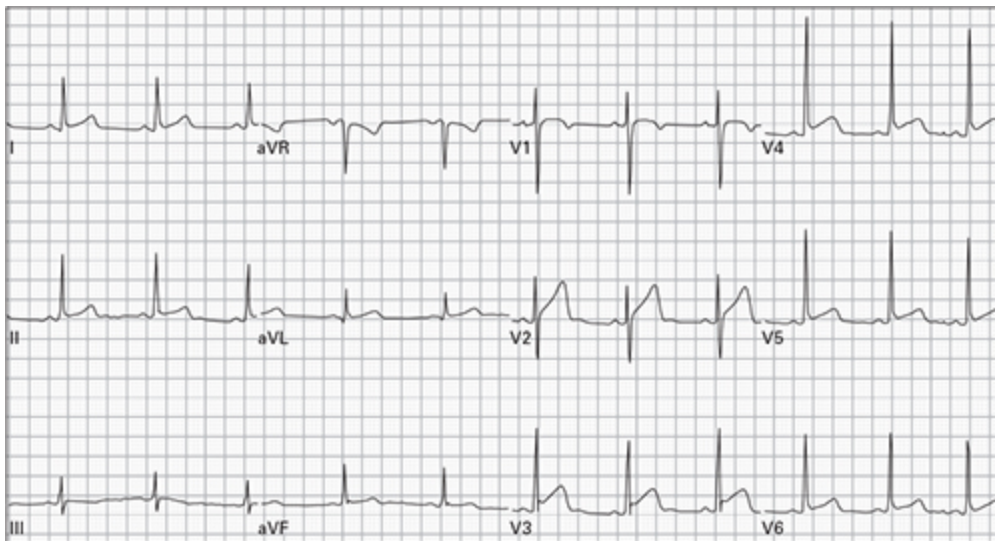
Part 1

Case histories

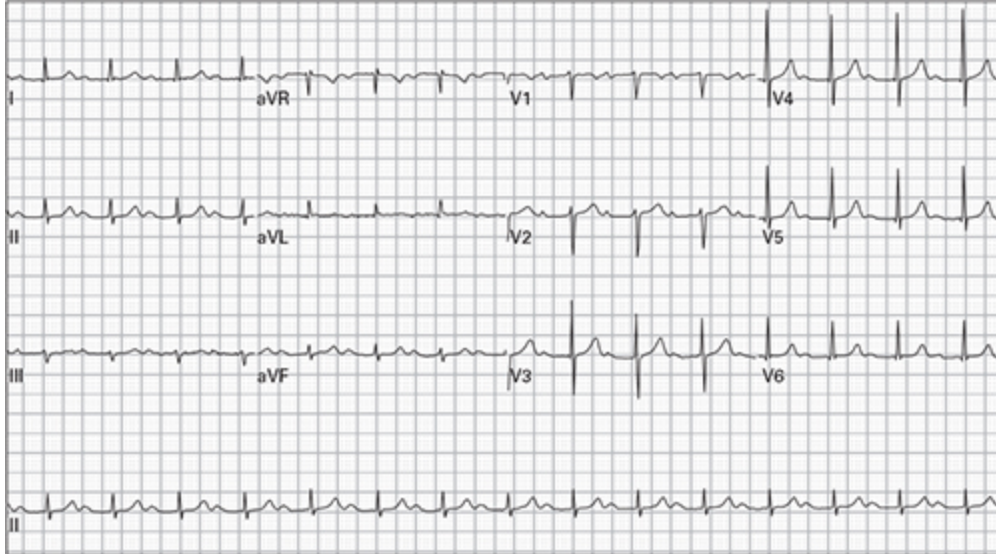
1. 45 year old woman, asymptomatic



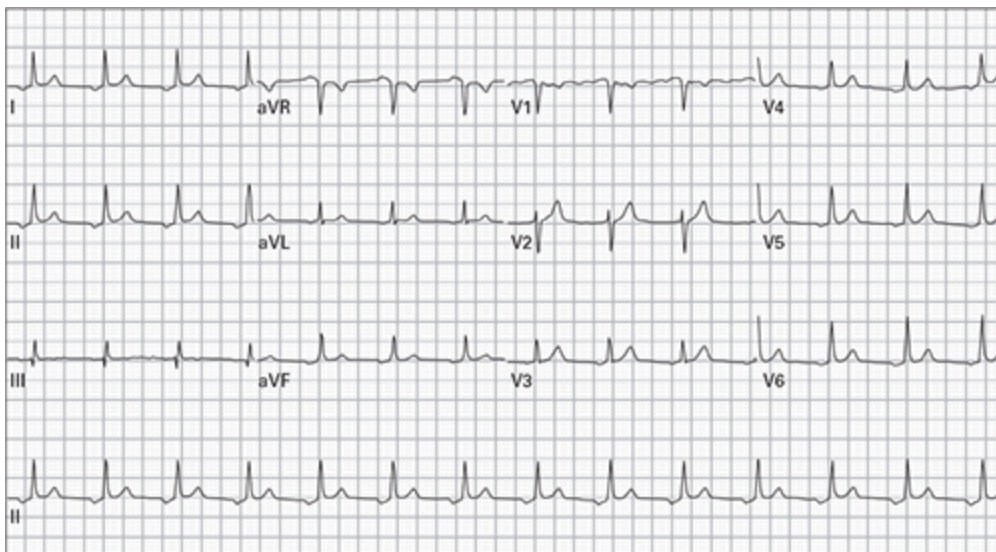
2. 24 year man with chest ache after lifting weights



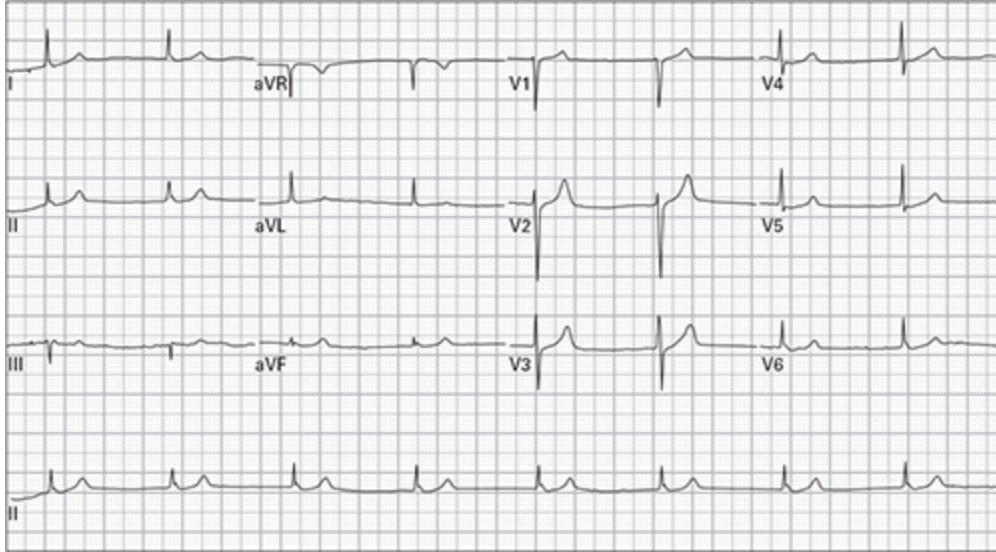
3. 76 year old man with dyspnea



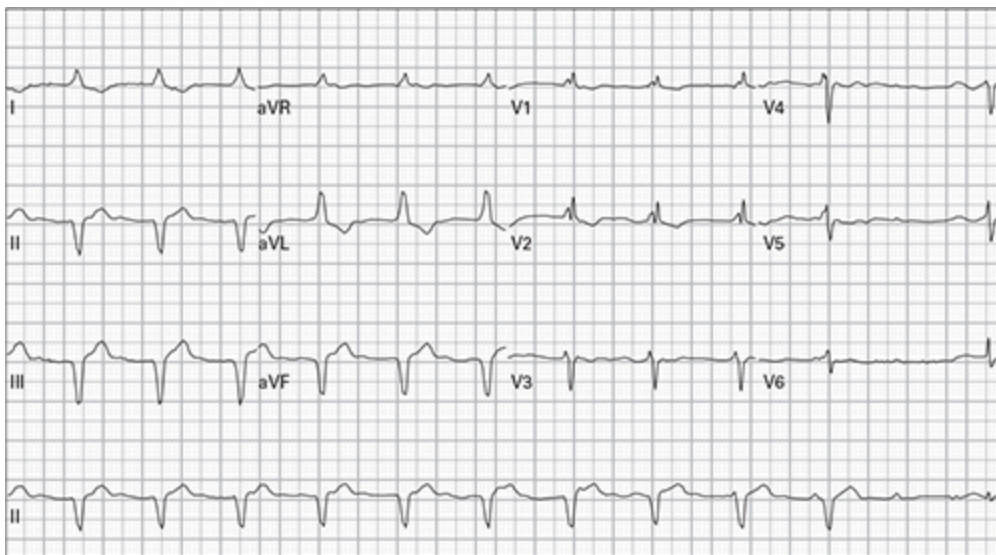
4. 64 year old man, asymptomatic



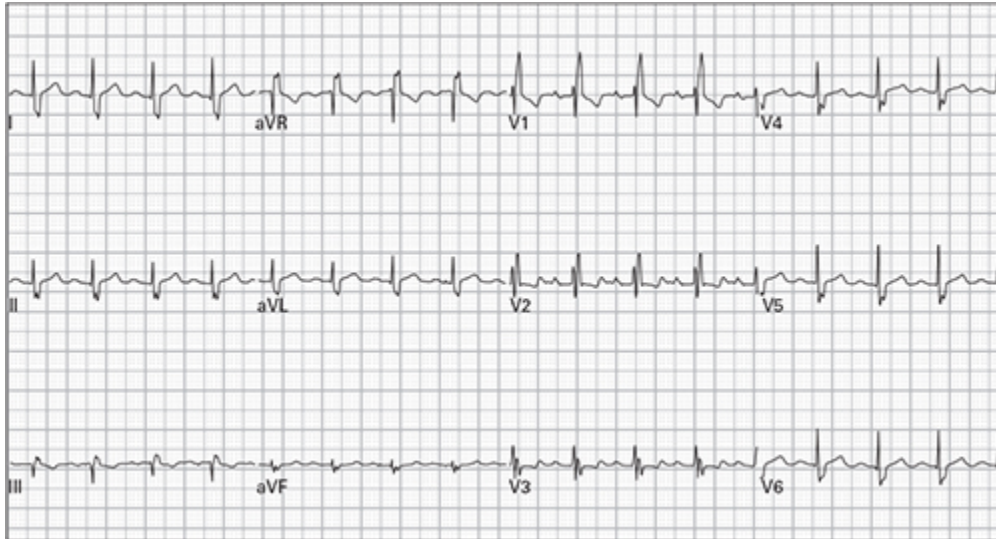
5. 48 year old woman reports severe lightheadedness with walking; she recently started a new medication for hypertension



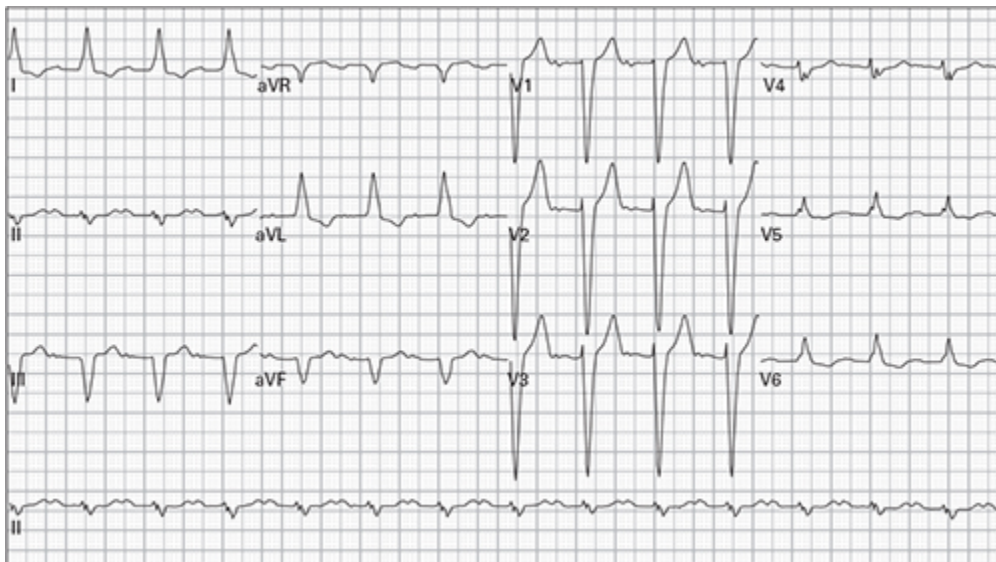
6. 79 year old man 45 minutes after receiving thrombolytic therapy for acute myocardial infarction; currently pain-free



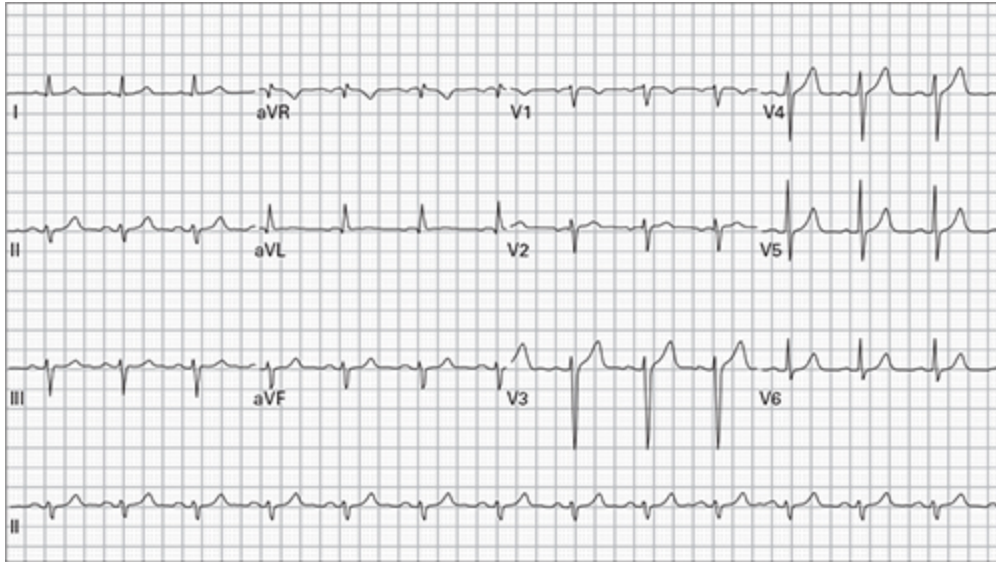
7. 43 year old man, asymptomatic



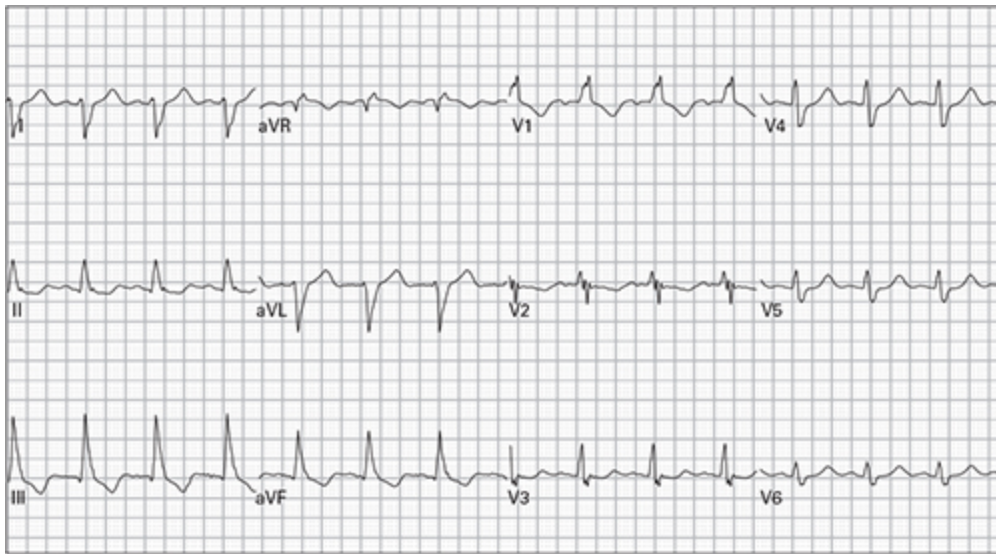
8. 82 year old man recently increased his dose of a beta-receptor blocking medication; he now reports exertional lightheadedness



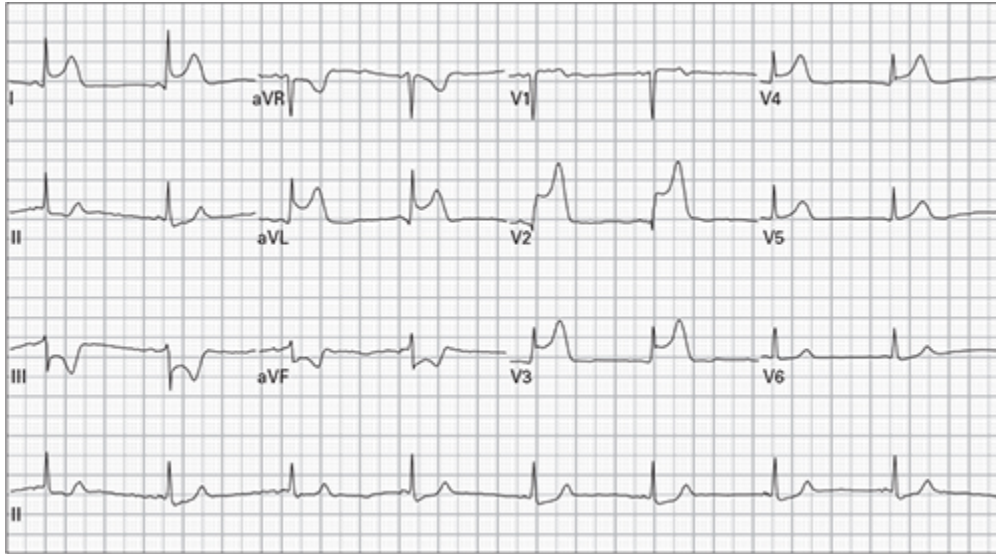
9. 49 year old man with occasional episodes of chest pain



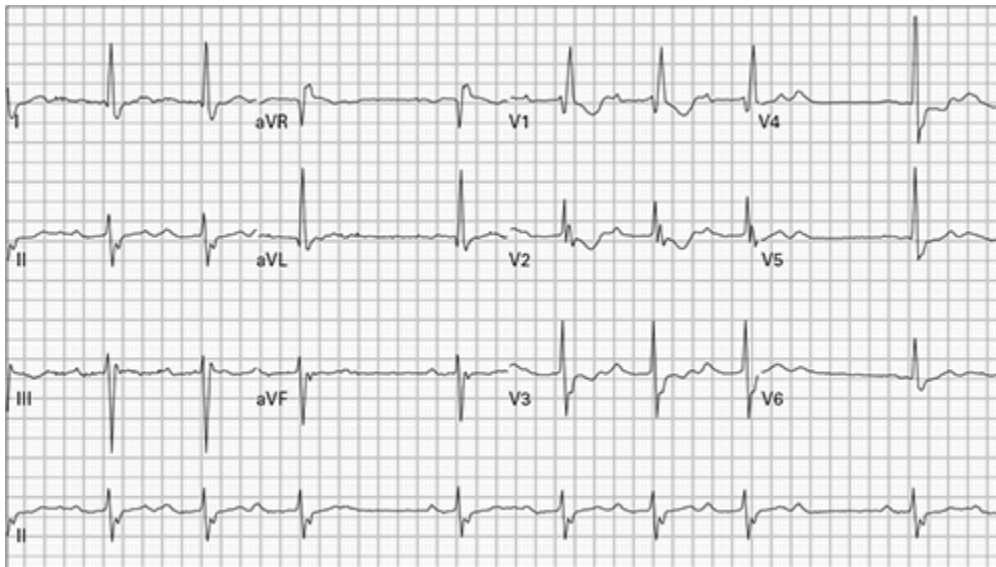
10. 65 year old woman with a long history of smoking presents for treatment of an emphysema exacerbation



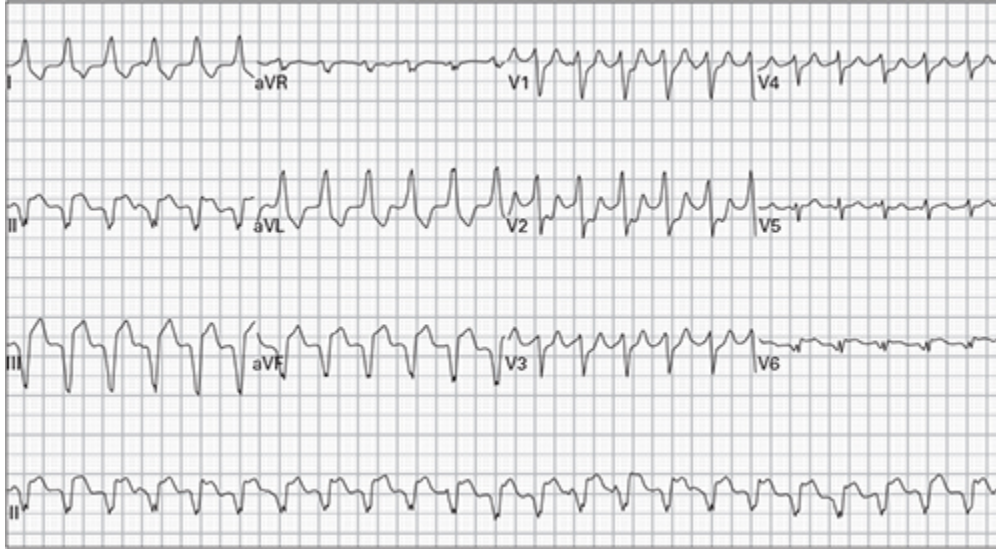
11. 54 year old woman complains of midsternal chest pain and lightheadedness



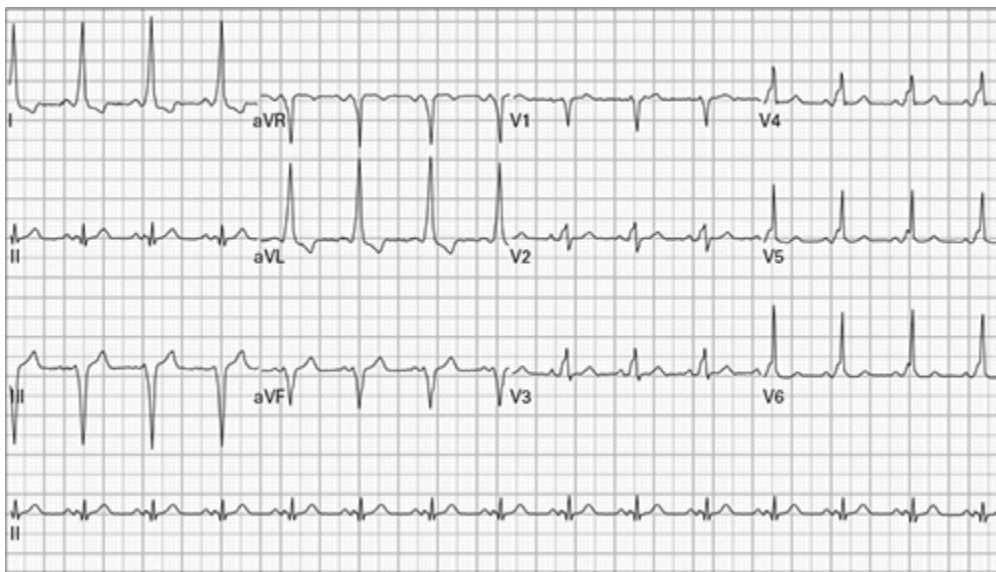
12. 86 year old woman complains of generalized weakness



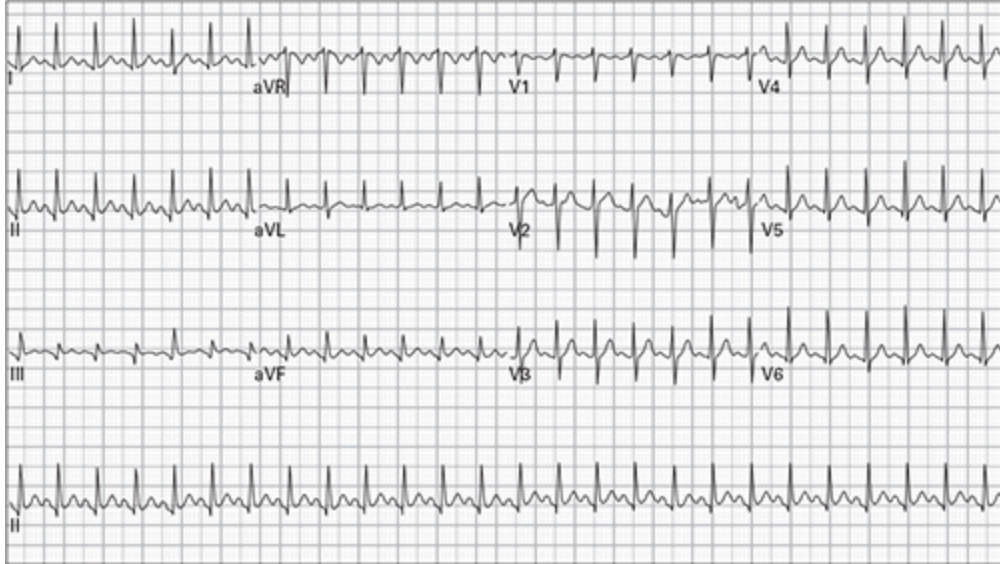13. 61 year old man with palpitations and lightheadedness



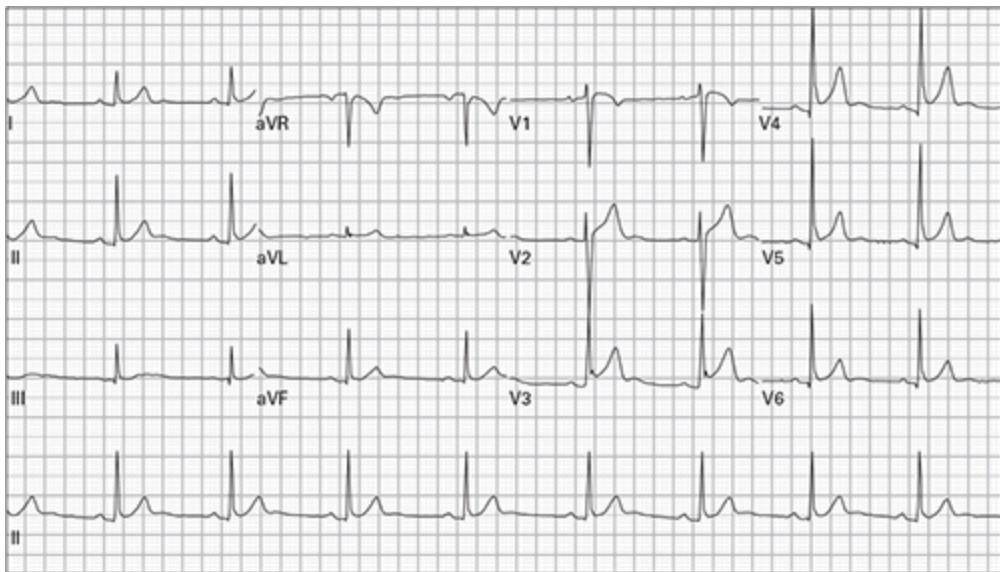
14. 44 year old woman with intermittent episodes of palpitations



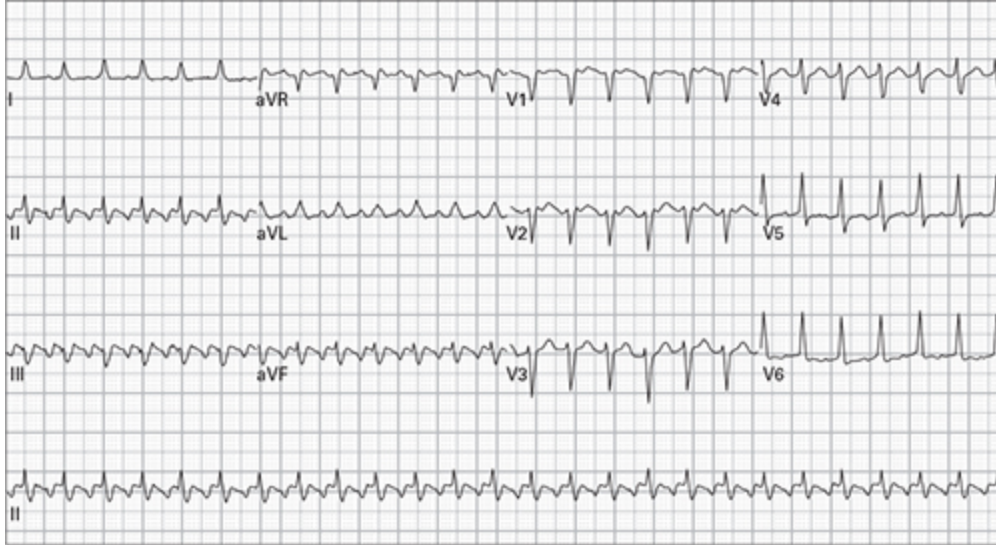
15. 24 year old pregnant woman with three days of frequent vomiting



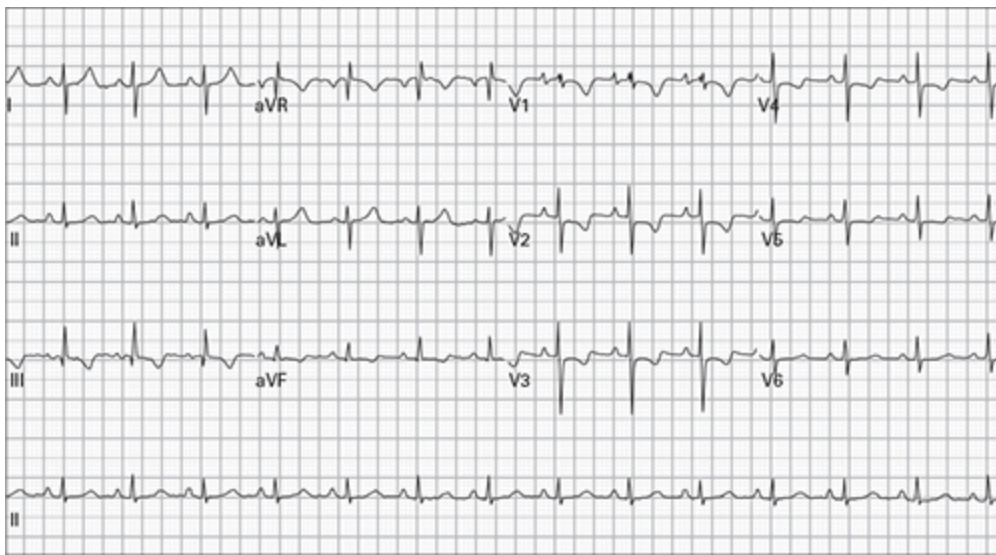
16. 37 year old man with pleuritic chest pain



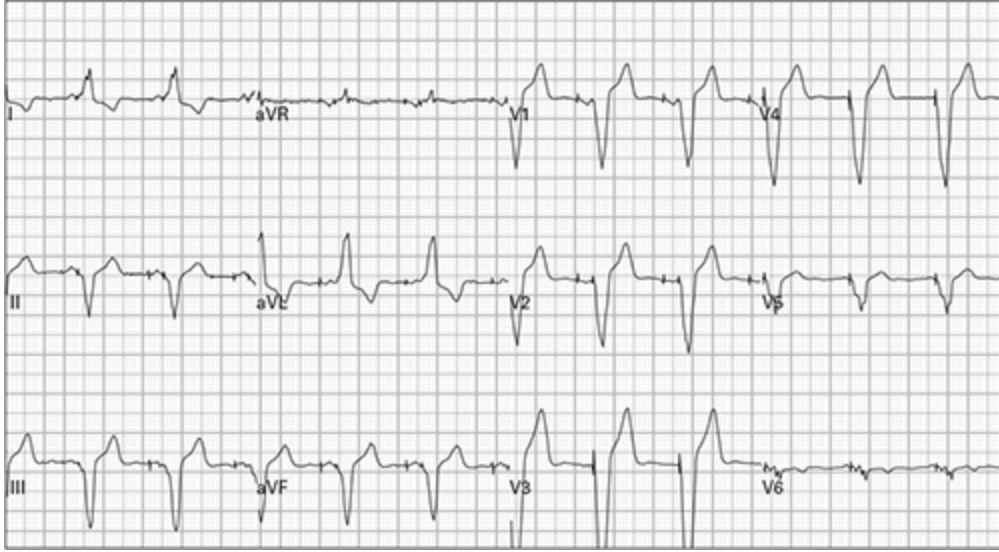
17. 63 year old man with palpitations and lightheadedness



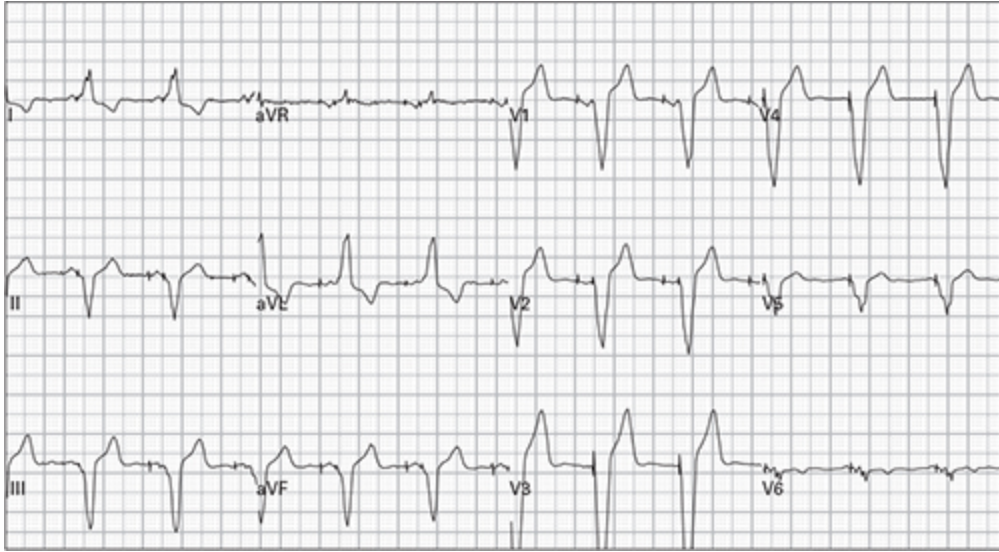
18. 33 year old obese man with sharp chest pain and dyspnea



19. 81 year old woman with palpitations and generalized weakness



20. 61 year old man, asymptomatic



21. 57 year old woman with mild chest pain and palpitations