

Radiological Anatomy for FRCR
Part 1

Philip Borg • Abdul Rahman Alvi

Radiological Anatomy for FRCR Part 1

 Springer

Philip Borg, MD
Radiology Department
C Floor
Royal Hallamshire Hospital
Glossop Road
Sheffield
S10 2JF
United Kingdom
philipborg@doctors.org.uk

Abdul Rahman Alvi, MBBS MRCS
Radiology Department
C Floor
Royal Hallamshire Hospital
Glossop Road
Sheffield
S10 2JF
United Kingdom
arjalvi@yahoo.com

ISBN: 978-3-642-13750-1

e-ISBN: 978-3-642-13751-8

DOI: 10.1007/978-3-642-13751-8

Springer Dordrecht Heidelberg London New York

Library of Congress Control Number: 2010932939

© Springer-Verlag Berlin Heidelberg 2011

This work is subject to copyright. All rights are reserved, whether the whole or part of the material is concerned, specifically the rights of translation, reprinting, reuse of illustrations, recitation, broadcasting, reproduction on microfilm or in any other way, and storage in data banks. Duplication of this publication or parts thereof is permitted only under the provisions of the German Copyright Law of September 9, 1965, in its current version, and permission for use must always be obtained from Springer. Violations are liable to prosecution under the German Copyright Law.

The use of general descriptive names, registered names, trademarks, etc. in this publication does not imply, even in the absence of a specific statement, that such names are exempt from the relevant protective laws and regulations and therefore free for general use.

Product liability: The publishers cannot guarantee the accuracy of any information about dosage and application contained in this book. In every individual case the user must check such information by consulting the relevant literature.

Cover design: eStudio Calamar, Figueres/Berlin

Printed on acid-free paper

Springer is part of Springer Science+Business Media (www.springer.com)

*To my wife Michela
my parents
Therisa and Maik
for their love, patience and guidance*

P.B.

To my parents, Anjum and Tariq, who provided me with a solid foundation in life and goals which I aspire to, to my wife Ayesha, for her patience and support throughout this endeavour and lastly to my children, Ibraheem and Zaynab, for being the coolness of my eyes.

A.R.J.A.

Foreword

Sound anatomical knowledge is the bed-rock of a good Radiologist. I am pleased to say that it is some while since I had to suffer the rigor of anatomical learning only then to be examined by humourless learned gentlemen of the College. The radiology consisted largely of dusted down plain radiographs, primitive CT and nuclear medicine composed of bricks rather than pixels (although that does not seem to have changed much).

Happily both imaging and the way that anatomy is examined have changed immeasurably. The preface deals with the change in the examination. Imaging has become more diverse and the anatomical detail is refined. This means that all students need to have an exquisite knowledge of anatomy in multiple planes using numerous imaging modalities. This book, and its associated on-line modules, parallels the new imaging and the way the curriculum is examined. The structure will not only give students of anatomy practice at the exam, but will also deliver an enjoyable way of learning.

Prof. PA Gaines
Hallam University and Sheffield Vascular Institute

Preface

The new format FRCR part 1 anatomy exam was introduced in March 2010. This book has been written to allow candidates to identify the level of anatomical knowledge expected by the college and to provide a self-assessment tool providing candidates with valuable practice before the exam. The aim of this book is to supplement, not replace established radiology anatomy text books and atlases.

In the exam the cases will be viewed using Osirix software on an Apple Mac mini workstation with a 19" monitor. The current format comprises 20 cases/images, with five questions about each. As a candidate you have 75 minutes in which to complete the exam. The images are labelled 1 to 20 and the five questions are labelled (a) to (e). You will be provided with a question booklet into which you write your answers. It is imperative that your answers are legible to secure full marks.

In depth knowledge and the ability to describe anatomy is an integral part of radiology. As in clinical practice, the college stresses the importance of labelling the correct side of the structure. For each question the RCR awards 2 marks, 1 mark is awarded for correctly naming the structure and another for describing the correct side.

We advise that you approach each image as if you were viewing these images in real life and adopt a system to interpret them thus ensuring that you have identified both the correct side and structure.

An axial section of a CT or MRI is displayed as if the body were viewed from below. In the current exam format, you are presented with a single slice of an image in the axial, sagittal or coronal plane. This sometimes may lead to ambiguity about the correct answer as you do not have the facility to scroll up and down the image to corroborate your answer. The RCR, in these instances, may allow for more than one correct answer.

The questions in this book have been arranged in a similar format to the exam and we have tried to cover all imaging modalities and included cases that are most likely to be assessed. We encourage attempting these tests under exam conditions. By working through each test we hope that you will gain confidence in your knowledge of the key topics as well as identify areas that may require further study. No cases have been repeated but some that are similar represent the cases that we think are important and likely to feature in the exam. In some instances, more than one correct answer has been listed to allow for the difference in nomenclature sometimes encountered.

Separate chapters on paediatric imaging and anatomical variants have been included as questions on these topics have been included in the previous examination.

Where appropriate, information has been provided after the answers including useful hints on how to accurately identify structures using various landmarks and aide-memoires. There is also information for questions other than 'name the structure' that may be asked. This information should aid further revision from the recommended textbooks and atlases currently available.

Finally, we wish you the best of luck in your exams and your careers.

P.B.
A.R.J.A.

We would appreciate comments and suggestions,
or if you have any queries, please email us on:
frcranatomy@gmail.com

Contents

1 Test 1	1
2 Test 2	29
3 Test 3	57
4 Test 4	83
5 Test 5	109
6 Test 6	137
7 Test 7	165
8 Test 8	193
Jane C Belfield	
9 Test 9: Paediatric Cases	221
Oshi Abeyakoon and Iwan Roberts	
10 Chapter 10: Normal Anatomical Variants	249
Jane C Belfield	

Contributors

Oshi Abeyakoon, MBBS BSc

Specialty Registrar in Clinical Radiology
Sheffield Radiology Training Scheme

Jane C Belfield, MB ChB MRCP

FRCR

Consultant Uroradiologist Radiologist
Royal Liverpool University Hospital
Co-Founder Yorkshire Radiology Courses

Matthew J Bull, MB ChB FRCR

Consultant Thoracic Radiologist
Sheffield Teaching Hospitals
Honorary Senior Clinical Lecturer
University of Sheffield

Daniel JA Connolly, BSc MRCP FRCR

Consultant Neuro-Radiologist Sheffield
Teaching Hospitals NHS Trust
Head of the School of Radiology
Yorkshire and the Humber Deanery
Honorary Senior Clinical Lecturer
University of Sheffield

Professor Peter Gaines, MB ChB

FRCP FRCR

Professor of Vascular Radiology
Sheffield Vascular institute
Consultant Vascular Interventional
Radiologist Sheffield Teaching Hospitals
Honorary Senior Clinical Lecturer
University of Sheffield

James Hampton, MBBS BSc M RAD

FRCR

Consultant Gastrointestinal Radiologist
Sheffield Teaching Hospitals NHS
Foundation Trust
Training Programme Director
Honorary Senior Clinical Lecturer
University of Sheffield

Richard Nakielny, MA BM BCH

FRCR

Consultant Radiologist Sheffield
Teaching Hospitals
Honorary Senior Clinical Lecturer
University of Sheffield

Iwan Roberts, FRCR

Consultant Paediatric Radiologist
Sheffield Children's Hospital
Honorary Senior Clinical Lecturer
University of Sheffield

Acknowledgments

Deepak Prasad (Consultant Radiologist
Bradford)

Wan Wan Yap (Radiology registrar Leeds)

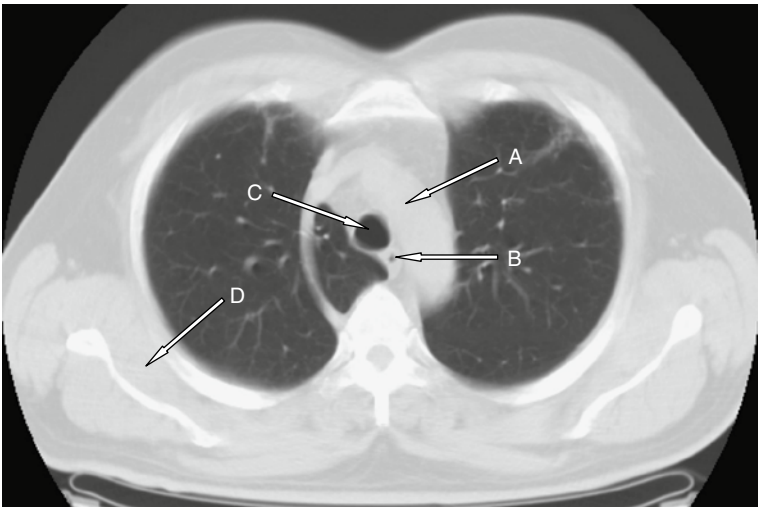
Test

1

You have 75 min to complete 20 cases

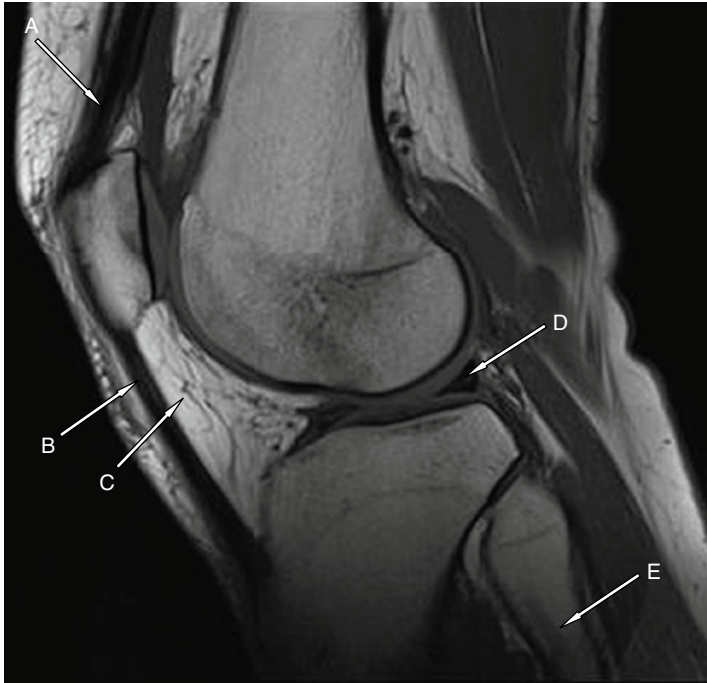
1

Case 1



Case 1		
	Question	Write your answer here
(a)	Name the structure labelled A	
(b)	Name the structure labelled B	
(c)	Name the structure labelled C	
(d)	Name the structure labelled D	
(e)	What normal variant is present in this image?	

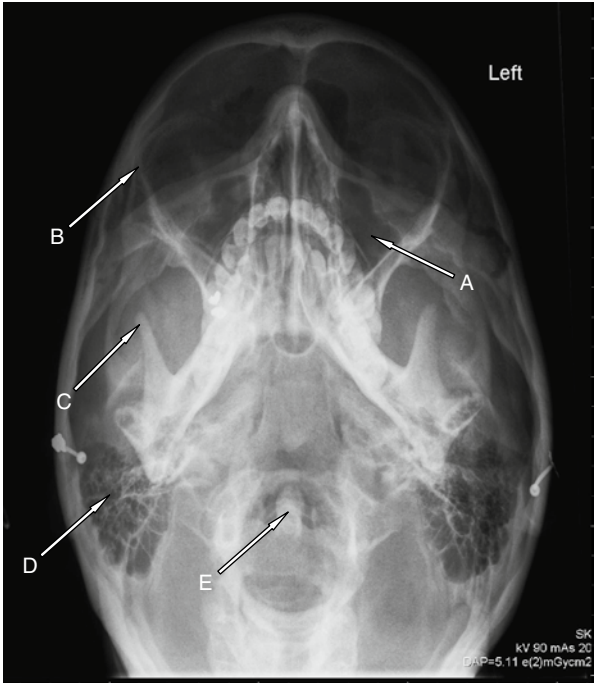
Case 2



Case 2		
	Question	Write your answer here
(a)	Name the structure labelled A	
(b)	Name the structure labelled B	
(c)	Name the structure labelled C	
(d)	Name the structure labelled D	
(e)	Name the structure labelled E	

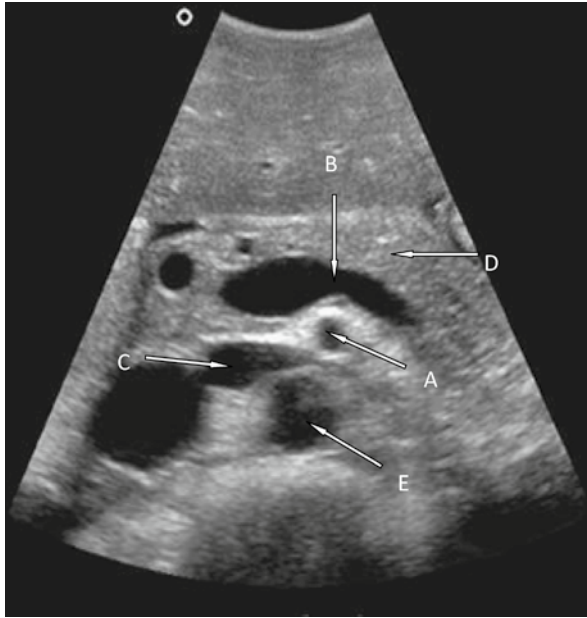1

Case 3



Case 3		
	Question	Write your answer here
(a)	Name the structure labelled A	
(b)	Name the structure labelled B	
(c)	Name the structure labelled C	
(d)	Name the structure labelled D	
(e)	Name the structure labelled E	

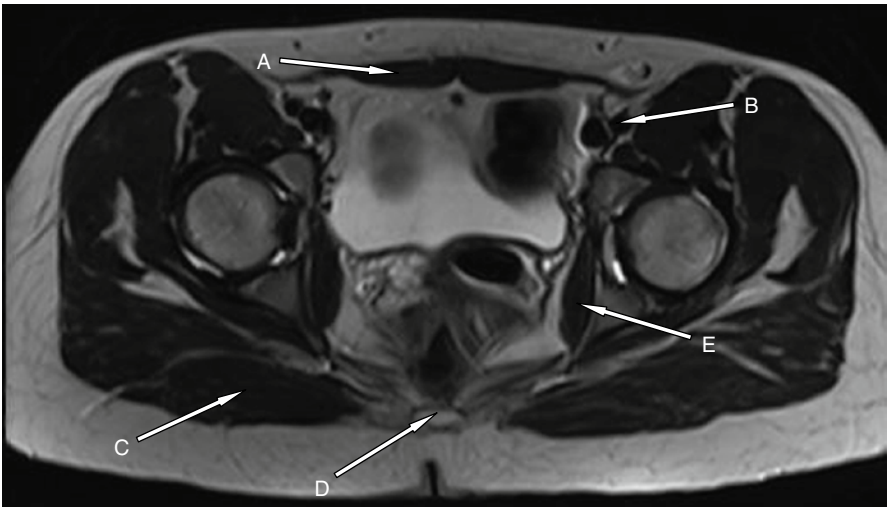
Case 4: Abdominal ultrasound



Case 4		
	Question	Write your answer here
(a)	Name the structure labelled A	
(b)	Name the structure labelled B	
(c)	Name the structure labelled C	
(d)	Name the structure labelled D	
(e)	Name the structure labelled E	

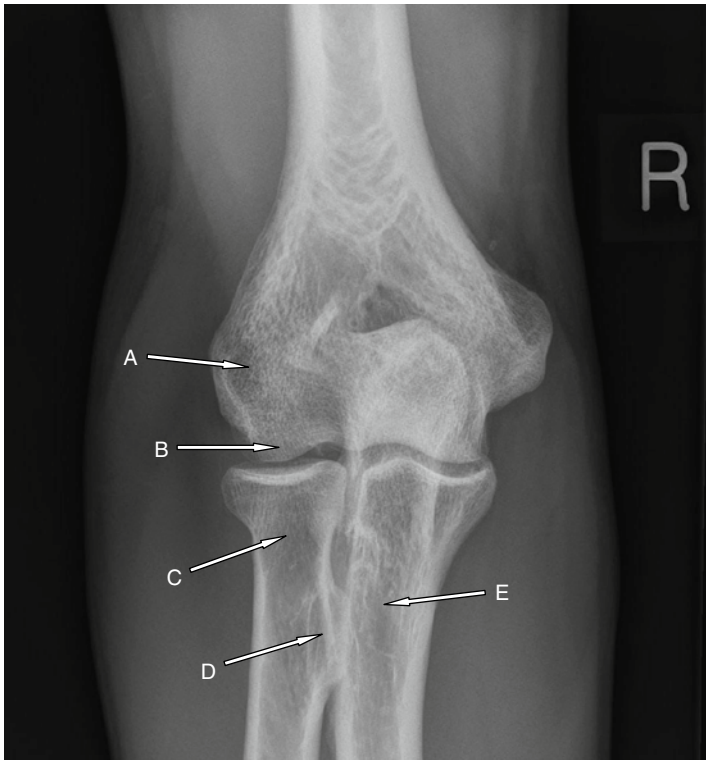
1

Case 5



Case 5		
	Question	Write your answer here
(a)	Name the structure labelled A	
(b)	Name the structure labelled B	
(c)	Name the structure labelled C	
(d)	Name the structure labelled D	
(e)	Name the structure labelled E	

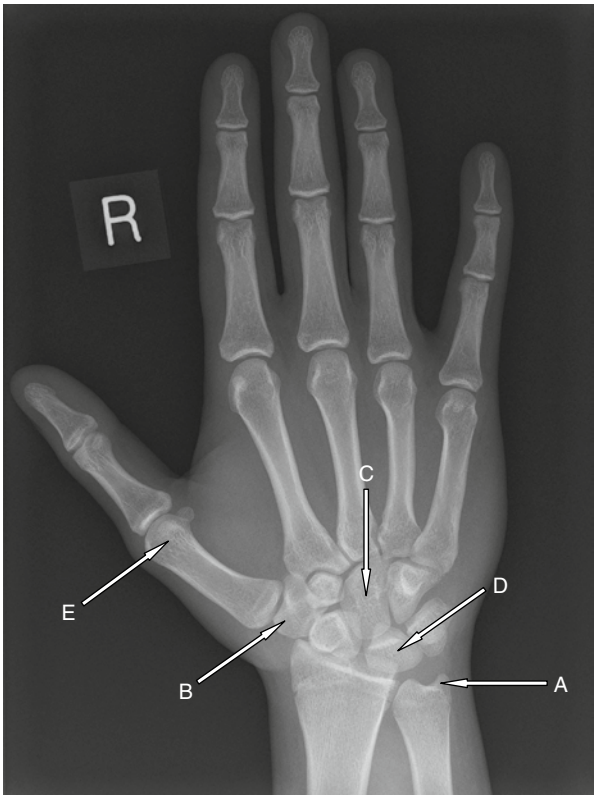
Case 6



Case 6		
	Question	Write your answer here
(a)	Name the structure labelled A	
(b)	Name the structure labelled B	
(c)	Name the structure labelled C	
(d)	What muscle inserts into structure D?	
(e)	Name the structure labelled E	

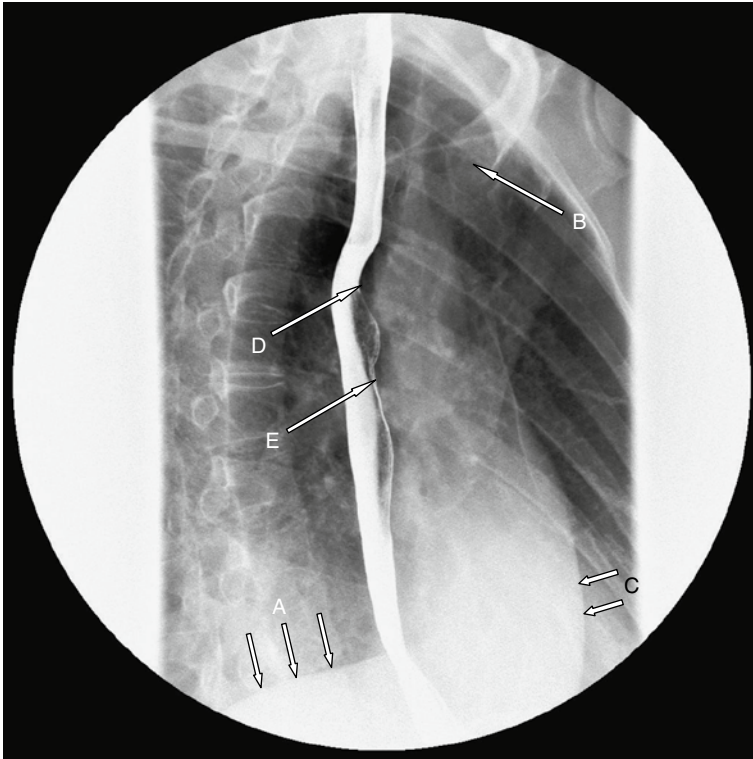
1

Case 7



Case 7		
	Question	Write your answer here
(a)	Name the structure labelled A	
(b)	Name the structure labelled B	
(c)	Name the structure labelled C	
(d)	Name the structure labelled D	
(e)	Name the structure labelled E	

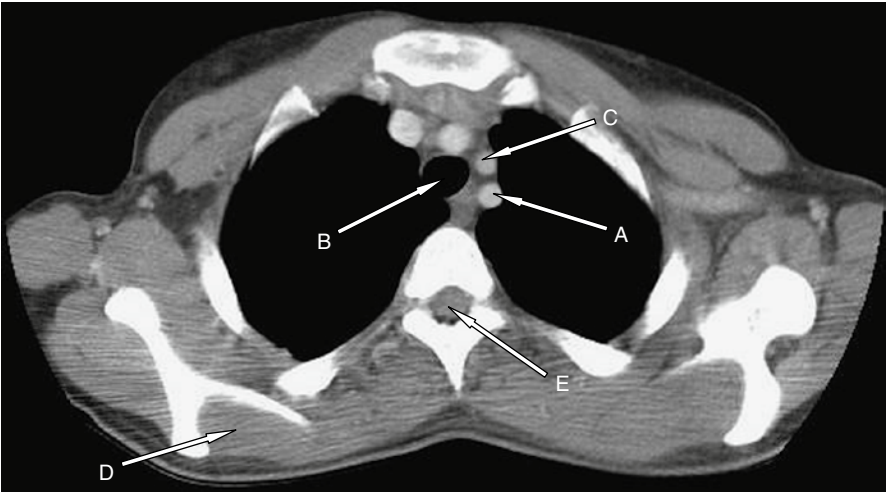
Case 8



Case 8		
	Question	Write your answer here
(a)	Name the structure labelled A	
(b)	Name the structure labelled B	
(c)	Name the structure labelled C	
(d)	What structure causes this impression?	
(e)	What structure causes this impression?	

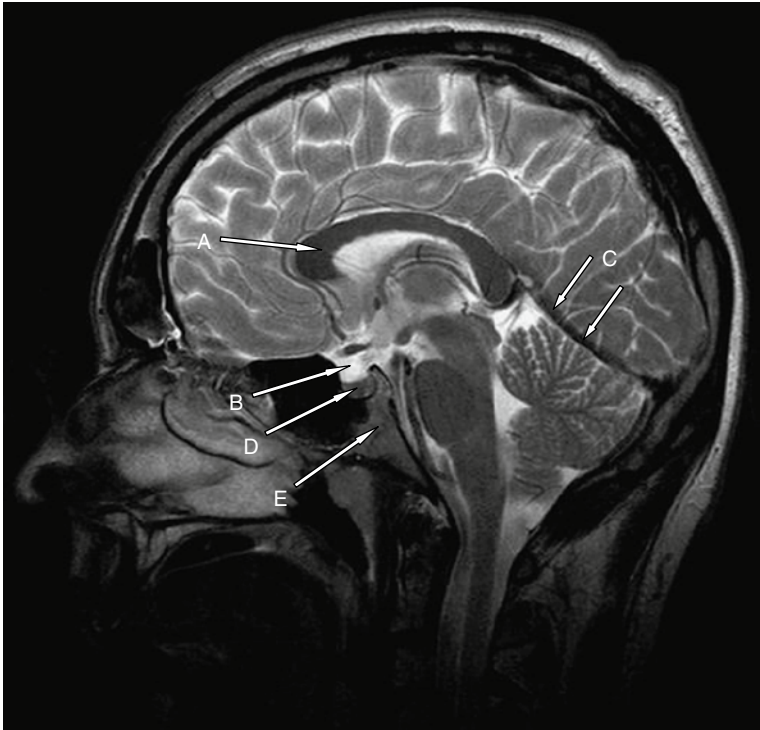
1

Case 9



Case 9		
	Question	Write your answer here
(a)	Name the structure labelled A	
(b)	Name the structure labelled B	
(c)	Name the structure labelled C	
(d)	Name the structure labelled D	
(e)	Name the structure labelled E	

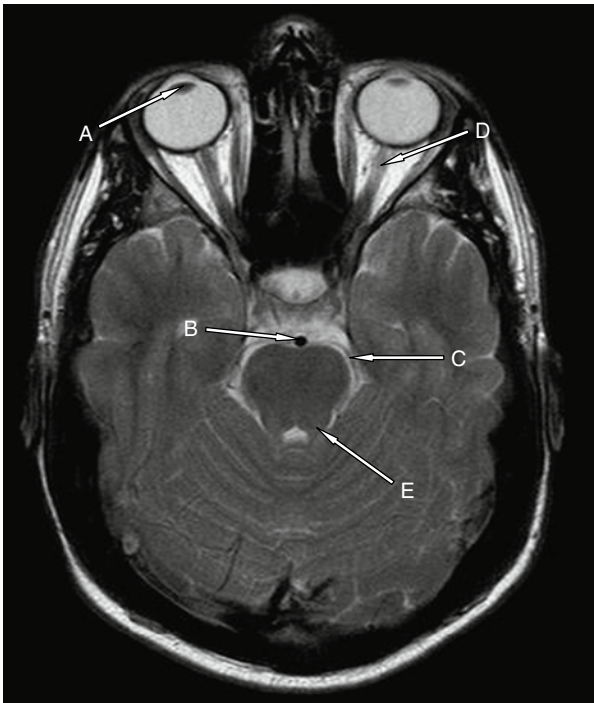
Case 10



Case 10		
	Question	Write your answer here
(a)	Name the structure labelled A	
(b)	Name the structure labelled B	
(c)	Name the structure labelled C	
(d)	Name the structure labelled D	
(e)	Name the structure labelled E	

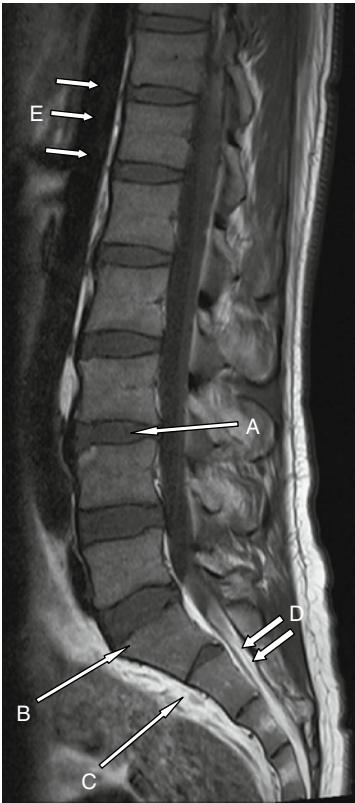1

Case 11



Case 11		
	Question	Write your answer here
(a)	Name the structure labelled A	
(b)	Name the structure labelled B	
(c)	Name the structure labelled C	
(d)	Name the structure labelled D	
(e)	Name the structure labelled E	

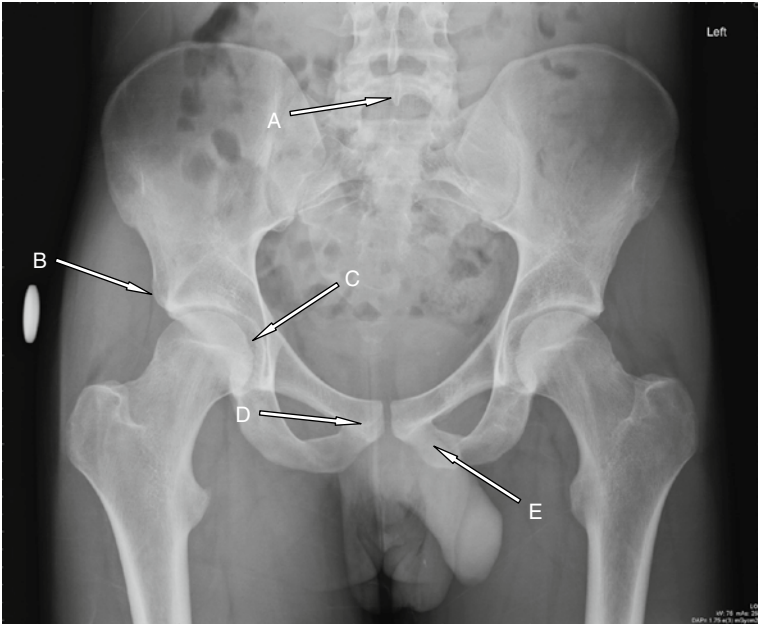
Case 12



Case 12		
	Question	Write your answer here
(a)	Name the structure labelled A	
(b)	Name the structure labelled B	
(c)	Name the structure labelled C	
(d)	Name the structure labelled D	
(e)	Name the structure labelled E	

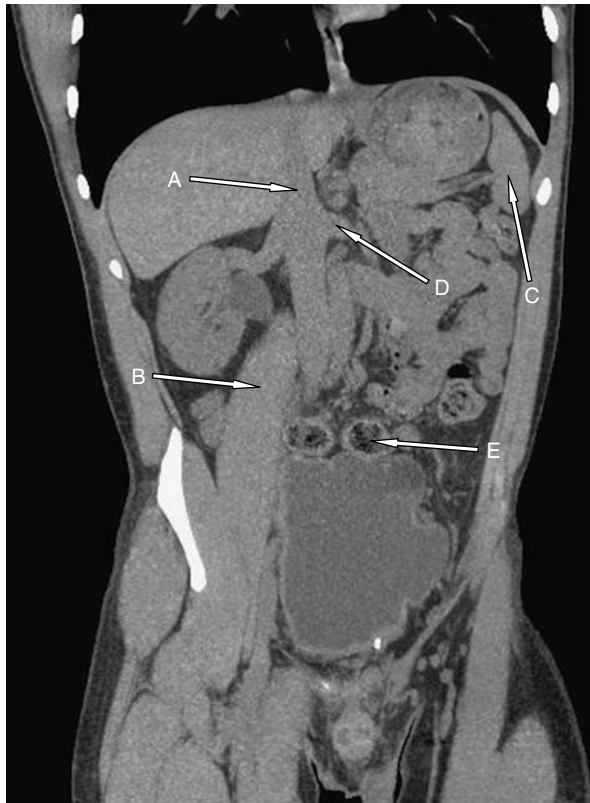1

Case 13



Case 13		
	Question	Write your answer here
(a)	Name the structure labelled A	
(b)	Name the structure labelled B	
(c)	Name the structure labelled C	
(d)	Name the structure labelled D	
(e)	Name the structure labelled E	

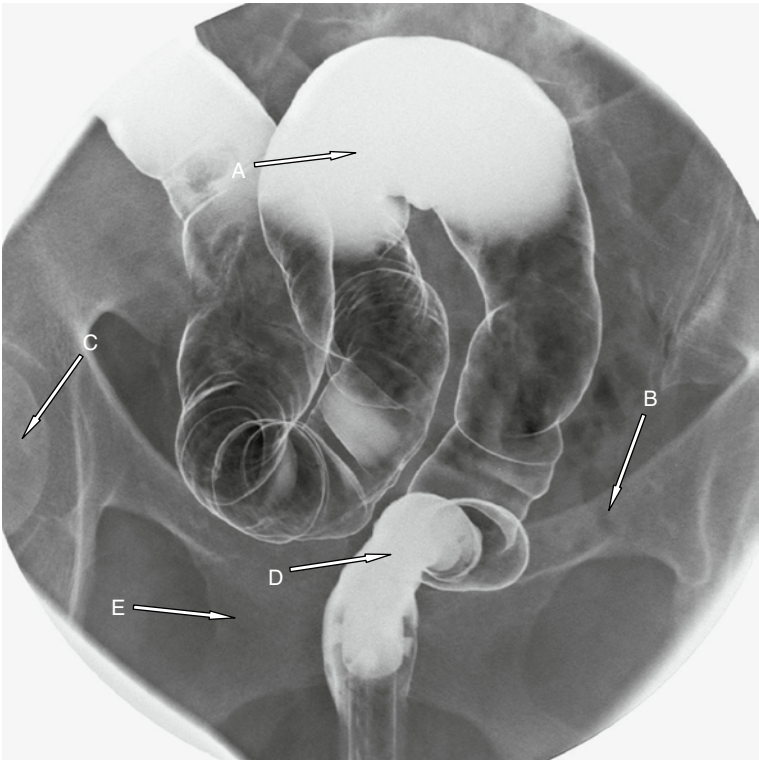
Case 14



Case 14		
	Question	Write your answer here
(a)	At what vertebral level does structure A traverse the diaphragm?	
(b)	Name the structure labelled B	
(c)	Name the structure labelled C	
(d)	Name the structure labelled D	
(e)	Name the structure labelled E	

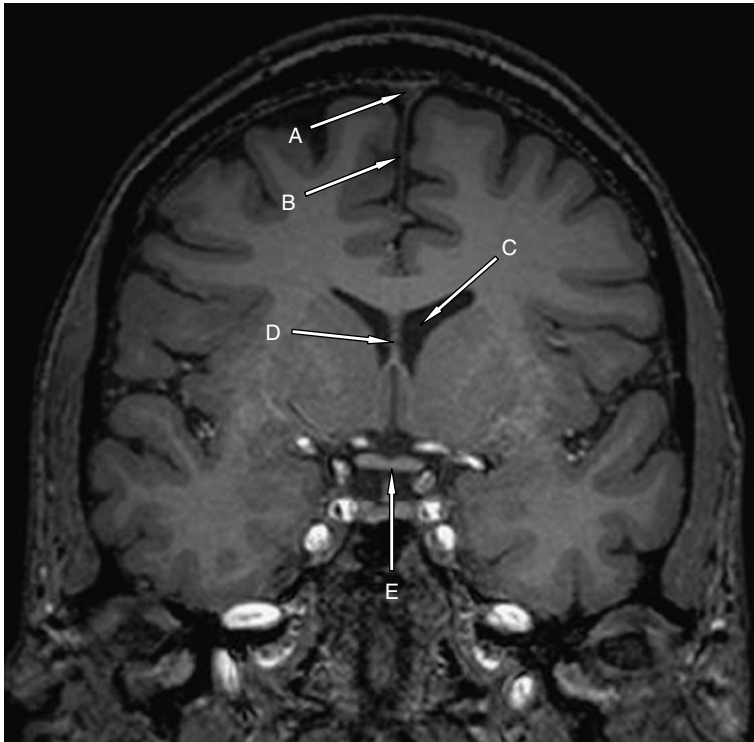
1

Case 15



Case 15		
	Question	Write your answer here
(a)	Name the structure labelled A	
(b)	Name the structure labelled B	
(c)	Name the structure labelled C	
(d)	Name the structure labelled D	
(e)	Name the structure labelled E	

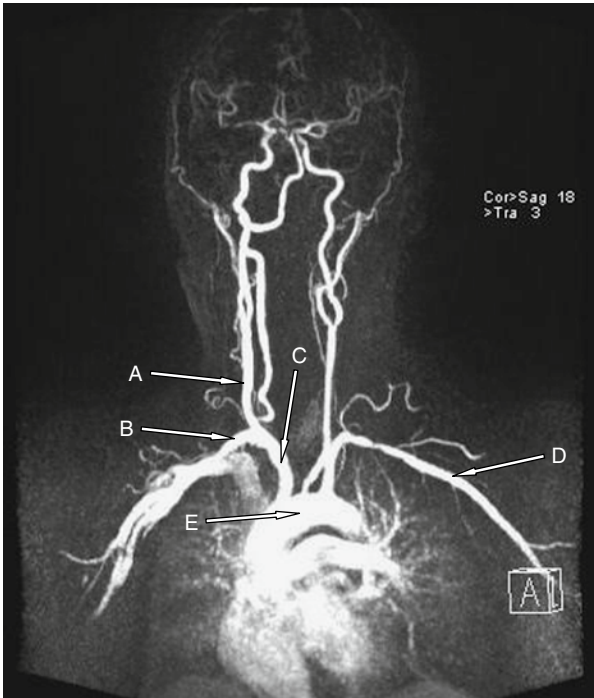
Case 16



Case 16		
	Question	Write your answer here
(a)	Name the structure labelled A	
(b)	Name the structure labelled B	
(c)	Name the structure labelled C	
(d)	Name the structure labelled D	
(e)	Name the structure labelled E	

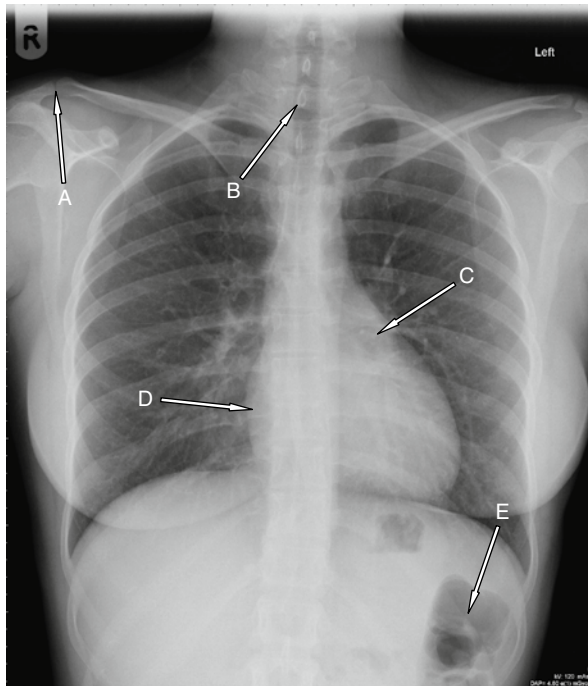
1

Case 17



Case 17		
	Question	Write your answer here
(a)	Name the structure labelled A	
(b)	Name the structure labelled B	
(c)	Name the structure labelled C	
(d)	Name the structure labelled D	
(e)	Name the structure labelled E	

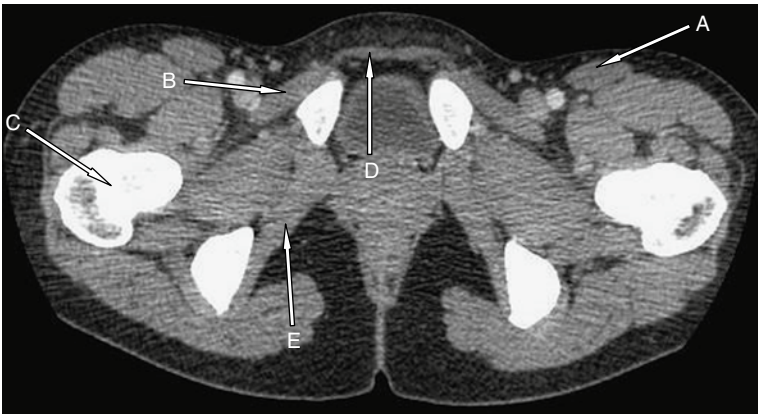
Case 18



Case 18		
	Question	Write your answer here
(a)	Name the structure labelled A	
(b)	Name the structure labelled B	
(c)	What part of the heart is labelled C?	
(d)	What part of the heart is labelled D?	
(e)	Name the structure labelled E	

1

Case 19



Case 19		
	Question	Write your answer here
(a)	Name the structure labelled A	
(b)	Name the structure labelled B	
(c)	Name the structure labelled C	
(d)	Name the structure labelled D	
(e)	Name the structure labelled E	